MACUB

IN VIVO

The Publication of the Metropolitan Association of College and University Biologists

Fall 2009 Volume 31, Issue 1

42nd ANNUAL NYMACUB CONFERENCE
Saturday, October 24, 2009
at
Kingsborough Community College, Brooklyn, NY

Keynote Addresses
Pandemic Flu and Emerging Infectious Diseases
by Debra Berg

Catching Fire: How Cooking Made Us Human
by Richard Wrangham

A Publication of the Metropolitan

Association of College & University Biologists
Serving the Metropolitan New York Area
for 43 Years

Instructions for Authors

IN VIVO is published three times yearly during the Fall, Winter, and Spring. Original research articles in the field of biology in addition to original articles of general interest to faculty and students may be submitted to the editor to be considered for publication. Manuscripts can be in the form of a) full length manuscripts, b) mini-reviews or c) short communications of particularly significant and timely information. Manuscripts will be evaluated by two reviewers.

Articles can be submitted electronically to *invivo@mec.cuny.edu* or mailed as a printed copy (preferably with a diskette that contains the file) to the Editorial Board at Medgar Evers College. All submissions should be formatted double spaced with 1 inch margins. The title of the article, the full names of each author, their academic affiliations and addresses, and the name of the person to whom correspondence should be sent must be given. As a rule, full length articles should include a brief abstract and be divided into the following sections: introduction, materials and methods, results, discussion, acknowledgments and references. Reviews and short communications can be arranged differently. References should be identified in the text by using numerical superscripts in consecutive order. In the reference section, references should be arranged in the order that they appeared in the text using the following format: last name, initials., year of publication. title of article, journal volume number: page numbers. (eg. - [1]Hassan, M. and V. Herbert, 2000. Colon Cancer. *In Vivo* **32:** 3 - 8). For books the order should be last name, initial, year of publication, title of book in italics, publisher and city, and page number referred to. (eg. - Prosser, C.L., 1973. *Comparative Animal Physiology*, Saunders Co., Philadelphia, p 59.). Abbreviations and technical jargon should be avoided. Tables and figures should be submitted on separate pages with the desired locations in the text indicated in the margins.

In This Issue:

You are invited to participate in the 42nd Annual Fall MACUB Conference. Proposals are being accepted for member paper presentations and poster presentations.

Member Paper Presentations

If you wish to make a paper presentation (20 minutes) to will discuss results of research or share ideas, send an abstract to Dr. Mohamed Lakrim or Dr. Sarwar Jahangir

Poster Presentations

If you or any of your students wish to make poster presentation, please use the MACUB Web site to submit it, www.macub.org

Call for Poster Judges

If you would like to be a poster judge at the conference, please call or email:
Dr. Mohamed Lakrim
718-368-5107, mlakrim@kingsborough.edu
or
Dr. Sarwar Jahangir
718-368-5743, sjahangir@kingsborough.edu

Conference Keynote Speakers

Debra E. Berg, M.D. is the Medical Director for the Healthcare Emergency Preparedness Program in the Bureau of Communicable Diseases for the NYC Dept. of Health and Mental Hygiene. She completed her internal medicine residency, chief residency and infectious diseases fellowship at Michael Reese Medical Center, University of Illinois, in Chicago, Illinois. Subsequent to her training she spent three years in academic medicine as an Associate Internal Medicine Residency Director at Michael Reese Medical Center. Her main areas of concentration were in HIV care, tropical medicine and hospital-acquired infections. From 1995 to 1997 she was an Epidemic Intelligence Service Officer at the Centers for Disease Control and Prevention. From 1997 to 2002 she worked in the DOHMH's Bureau of Tuberculosis as the Director of Medical Affairs. In 2001, she was active in the public health response after the World Trade Center attack and was the physician-in-charge for the *New York Post* media site anthrax investigation. Over the last 7 years she has been the Medical Director of the Healthcare Emergency Preparedness Program to oversee the distribution of federal Healthcare Preparedness monies used to fund and monitor NYC medical facilities' planning and response initiatives for biologic, chemical, radiological, explosive, and coastal storm emergencies. She oversaw the healthcare response activities during the novel H1N1 influenza outbreak. Her keynote address will be *"Pandemic Flu and Emerging Infectious Diseases".*

Richard W. Wrangham is a Brithish primatologist. He is the Ruth Moore Professor of Biological Anthropology at Harvard University and his research group part of the Department of Human Evolutionary Biology.

He is co-director of the Kibale Chimpanzee Project, the long-term study of the Kanyawara chimpanzees in Kibale National Park, Uganda His research culminates in the study of human evolution in which he draws conclusions based on the behavioural ecology of apes. He is the co-author of a book entitled Demonic Males: *Apes and the Origins of Human Violence* with Dale Peterson. As a graduate student, Wrangham studied under Robert Hinde and Jane Goodall.

Along with Eloy Rodriguez, Wrangham helped to introduce the concept of zoopharmacognosy. Wrangham is considered "one of the pioneers of the study of chimp self-medication."

Dr. Wrangham's keynote will be "Catching Fire: How Cooking Made Us Human" which will focus on the role cooking has played in human evolution.

KINGSBOROUGH COMMUNITY COLLEGE

Kingsborough Community College is located on a 70-acre campus on Manhattan Beach, on the southern tip of Brooklyn, New York. Founded in 1963, the College serves approximately thirty thousand students per year, offering a wide range of credit and non-credit courses in the liberal arts and career education, as well as a number of specialized programs. The breathtaking Kingsborough Community College campus overlooks three bodies of water: Sheepshead Bay, Jamaica Bay and the Atlantic Ocean. Kingsborough serves a widely diverse student population and is in the top ten community colleges in the country in associate degrees awarded to minority students.

Kingsborough Community College is a comprehensive community college, offering a broad array of educational opportunities in line with its current mission: preparation for transfer to a four-year institution, career development, general education, adult and continuing education, and support services.

The Department of Biological Sciences

Programs at Kingsborough Community College provide biology majors with an excellent foundation to transfer to 4-year colleges and universities, and to transfer to professional schools in the allied health sciences. With a wide variety of degree offerings and concentrations, students have many ways to launch a career in the exciting and constantly expanding field of biology.

Our courses promote student understanding of modern biological principles, encourage independent thinking, deepen understanding of biology's relevance to modern societal issues, and encourage personal growth in scientific writing and research. Most courses have Internet components to improve students' analytical powers and information technology skills valuable for success in life beyond college.

The Department offers several degree programs including an A.S. in Biology, an A.S. in Biotechnology, and an A.A.S. Physical Therapist Assistant Program. There are a wide range of biology courses for students of the liberal arts including General Biology, Human Genetics, Nutrition, Ecology, and the Biology of Aging. It is the Department's goal to provide each student at Kingsborough, not only biology majors, with course choices and the basics for a broad, well-informed education in the life sciences. Formal articulation agreements exist with Brooklyn College and Medgar Evers College assuring a seamless transfer opportunity for our students without any loss of credit for those who successfully complete the required degree program. The A.S. degree program in Biotechnology is unique in that it prepares students to directly enter the workforce as Biotechnicians upon completion of their degree or the option to transfer to a 4 year institution to complete their baccalaureate degree and pursue graduate studies if they so desire.

Motivated and talented students have an opportunity to take part in faculty research projects. Departmental awards and honors are presented annually to students with outstanding academic records.

The Vascular Flora of the Florida Scrub as Reported in the Novel, "The Yearling"

by

Richard Stalter[1] and Jackeline Urrutia
[1]Department of Biology
St. John's University, Queens, NY 11439

ABSTRACT

The objective of this study was to identify the vascular plant species of the Florida scrub as reported by Marjorie K. Rawlings in her novel "The Yearling", set in Volusia County, north central Florida, around 1870. She included 98 species in 76 genera in 49 families in the novel. The largest families in the flora were the *Ericaceae* (9 species) and *Asteraceae* (7 species). The largest genera in the flora were *Vaccinium* and *Quercus*, each with 4 species. Ten species have medicinal properties: *Aletris lutea, Cymbopogon citratus, Salvia lyrata, Sarracenia minor, Sanicula canadensis, Serenoa repens Stillingia sylvatica, Verbascum thapsus, Phytolacca americana,* and *Zanthoxylum clava-herculis.*

Key words: The Yearling, Florida scrub, vascular plant species

Introduction

The Yearling, a Pulitzer Prize winning novel by Marjorie Kinnan Rawlings, was set in the scrub, Volusia County, Florida around 1870. The novel is centered around the relationship between Jody Baxter, a 12 year old boy, his tame fawn Flag and his family[1]. The Yearlings author, M.K. Rawlings, lived near the setting of the novel for 25 years. She was well acquainted with the people and the scrub environment as she, too, lived and coped with life in northeast rural Florida for 25 years. In her novel she described the daily habits of the Baxters, a backwoods family, as they struggled to eak out a living in the harsh scrub environment. Rawlings described many vascular plant species encountered by the Baxters, "Penny" (Ezra) Jody and his mother, "Ory" during the year which Jody passed from boyhood to painful manhood. The objective of this paper was to prepare a list of the vascular plant species encountered by the Baxters in the Florida scrub. Additional objectives were to determine the medicinal plants, their therapeutic properties and their utility.

Climate

The climate of north central Florida is subtropical[2]. Summers are warm and humid with frequent thunder showers. Winters are warm because of the southern latitude and proximity of the warm Atlantic Ocean. July and August are the warmest months, both with a mean temperature of 27.2ºC. January is the coldest month with an average of 14.2ºC. Rainfall averages 1465 mm/year; most falls in the four summer months, June to September. June, the wettest month, receives an average of 205mm of rain while December, the driest month but 62mm. Most of the summer rain occurs as local thunderstorms which can drop the temperature from 5.56-11.12°C during the storm. These storms generally occur during the hottest part of the day but are the short duration rarely lasting more than one or two hours. During infrequent hurricanes, rainfall over 20 inches, 508mm, is not uncommon. Most hurricanes last but a day or two, unlike the hurricane that raged for a week in the novel. A hurricane bringing torrential rains for a week would be highly unlikely since hurricanes are generally fast moving storms that rarely last more than a day at a particular site.

The growing season is long generally running from early March to mid November. Frost can be expected 13 days during the winter. The growing season at the Baxter's land is actually shorter than that of Charleston, South Carolina where the moderating effect of the Atlantic Ocean generally prevents the first fall frost from occurring before late November. The last winter frost at Charleston usually falls around the end of February.

Methods

The Yearling was the source of common names of vascular plant species in the Scrub in north central Volusia County. Various manuals were consulted as references for the common names of the species encountered in the novel. These included Fernald[3], Radford Ahles and Bell[4], and Wunderlin[5,6]. Richard Wunderlin and John Nelson also provided common names for species not listed in the aforementioned manuals. The medicinal properties of the taxa used as folk remedies in the novel are listed in Table 2. Many additional vascular plant species listed in the Yearling have medicinal properties, but these were not utilized as such in the novel. A third table lists plants and their common utility other than medicinal.

Nomenclature primarily follows Wunderlin[6]. Taxonomic revisions in Kartesz[7] were also consulted to update the nomenclature in the flora. When the currently accepted name is different, the name as presented in Wunderlin[6] immediately follows, enclosed in brackets.

Results and Discussion

The vascular flora of the Florida Scrub listed in the Yearling was composed of 98 species in 76 genera in the 49 families. The largest families in the flora were the *Ericaceae* (9 species) and the *Asteraceae* (7 species). The largest genera were *Vaccinium* and *Quercus*, each with 4 species and *Pinus* with 3 species. Six species, *Brassica juncea*, *Citrus aurantium*, *Cymbopogon citratus*, *Melia azederach, Morus alba,* and *Prunus persicaria* were not native to the region, 6% of the flora. Ornamentals mentioned in the novel that have not become naturalized were not included in this flora. Though alien weedy vascular plant species were likely present in the Baxter's garden, none were listed by common name.

Non-native vascular plant species probably composed a smaller percentage of the vascular flora of Florida Scrub in 1870 than they do today. Stalter et al[8] surveyed the vascular flora of ten Indian Shell Midens from South Carolina to Florida. They reported 26 non-native species 11 percent of midden flora. Lamont and Stalter[9] reported a significant difference in the percentage of non-native vascular plant species at two sites within Orient Beach State Park, (OBSP) New York. The eastern site at OBSP, utilized by visitors, contained 113 non-native vascular plant species 47 % of the species. The second site, the western site, off-limits to visitors, contained 28 non-native species, 17% of the species identified at this site.

There are a large number of novels set in the South. Pines were mentioned taking over fallow fields during the Civil War at the O'Hara's plantation, Tara, in Margaret Mitchell's, "Gone With The Wind". Several species, notably *Sabal palmetto* and *Myrica cerifera*, were mentioned in E.A. Poes, "The Gold Bug" in the vicinity of Fort Moultrie, South Carolina, when Poe was stationed there[10].

Ten medicinal plants were mentioned in the novel (Table 2). Two species, *Aletris lutea* (Colic Root) and *Cymbopogon citratus* (Fever Grass) exemplify the use of thse taxa as a home remedy. *Zanthoxylem clava herculus* (Prickly Ash) was brewed as a tonic. Another name for *A. clava herculus* isTooth Ache Tree; Richard Stalter can personally attest to its mouth numbing properties. The fruit of *Serenoa repens*, (Saw palmotto) when mixed with rum, and allowed to sit over time produces an even stronger libation than rum alone.

Eleven additional plants were included for utility. Some are rather obvious such as the use of tree products, *Pinus* (Pine) for wood

Table 1. The vascular plant species of the Florida Scrub mentioned in The Yearling					
	Spore plants	**Conifers**	**Dicots**	**Monocots**	**Total**
Families	1	2	37	8	49
Genera	1	3	59	13	76
Species	1	5	77	15	98
Native species	1	5	72	14	92
Introduced species	0	0	5	1	6
[1]Native and introduced taxa that reproduce spontaneously					

Table 2. A list of medicinal plants and some of their therapeutic properties		
Species	Common Name	**THERAPEUTIC VALUE**
Aletris lutea	Colic Root	Colic
Cymbopogon citratus	Fever grass	Fever
Salvia lyrata	Cancer Weed	
Phytolacca americana	Poke Berry	
Sanicula canadensis	Black snake root	Stimulant, expectorant
Sarracenia minor	Pitcher Plant	
Serenoa repens	Saw Palmetto	Tonic
Stillingia sylvatica	Queen's Root	Alterative, in decoction
Verbascum thapsus	Mullein	
Zanthoxylum clava-herculis	Prickly Ash	Tonic, fluid extract

Table 3. A list of plants and their utility		
Species	**Common Name**	**Use**
Aristida spp.	Wire grass	Hat
Crataegus aestivalis	May Haw	Jelly
Cyrilla racemiflora	Titi	Broom
Typha spp.	Cattail	bedding
Tillandsia usneoides	Spanish Moss	bedding, scouring
Pinus spp.	Pine	wood-bedding
Sabal palmetto	Palmetto	Broom, Hat
Serenoa repens	Saw Palmetto	“Tonic”
Taxodium distichum	Cypress	boat, buckets
Tephrosia virginiana	Rabbit Pea	Halter
Quercus alba	White Oak	Ox yoke

and *Taxodium distichum* (Bald Cypress) for boat building. The fruit of *Crataegus* (Hawthorne) and *Smilax* (Briar) was used for jelly. *Aristida* (Wire Grass) was employed in hat making; its use is similar to the current use of another grass, *Muhlenbergia capillaris* (and *M. filipes*) the principal component in the production of Gullah baskets by African Americans around Charleston and Mt. Pleasant, South Carolina today. *Tillandsia usneoides* (Spanish Moss) was used as bedding and scouring material; today it is commonly used as "potting material" for faux plants.

The large number of vascular plant species, 98 mentioned in The Yearling, may be attributed to the authors closeness to nature, and her interest, and knowledge of the local flora during her 25 year stay at "Cross Creek" in north central Florida.

ANNOTATED CHECKLIST OF SPECIES

The vascular plant taxa have been arranged according to the following categories: vascular cryptogams, gymnosperms, dicots, and monocots. Within each category, families and lower taxa are arranged alphabetically. Nomenclature primarily follows Wunderlin[6]; taxonomic revisions of Kartesz[7] were consulted to update the nomenclature. Non-native species are noted with an asterisk (*). Questionable species are noted with a question mark.

POLYPODIOPHYTA
Pteridaceae
Pteris tripartata (Sw.) Presl Giant Bracken (Fern)
PINOPHYTA
Cupressaceae
Juniperus virginiana L. var. *silicicola* (Small) E. Murray [*J. silicicola* (Small) Bailey]. Southern Red Cedar
Taxodium distichum (L.) Rich. [Previously included in the Taxodiaceae]. Bald Cypress, Cypress
Pinaceae
*Pinus clausa (*Chapman ex Engelm.) Vasey ex Sarg. Sand Pine
Pinus palustris Mill. Long Leaf Pine
Pinus taeda L. Yellow Pine

MAGNOLIOPHYTA - MAGNOLIOPSIDA
Aceraceae
Acer rubrum L. Swamp Maple
Anacardiaceae
Rhus copallina L. Sumac
Annonaceae
Asimina spp. Pawpaw
Asimina reticulata Chapm. Pawpaw
Apiaceae
Sanicula canadensis L. Snakeroot; Blacksnakeroot.
Apocynaceae
Apocynum cannabinum L. Dogbane
Aquifoliaceae
Ilex glabra (L.) A. Gray Gallberry
Ilex opaca Aiton American Holly
Asteraceae
Alteris lutea Small Colic Root (Yellow Colicroot)
Alteris obovata Nash Southern Colicroot
Anthemis cotula L. Dog Fennel
Aster spp. Aster
Baccharis halimifolia L. Sea Myrtle
Erechtites hieracifolia (L.) Raf. Fire Weed (Fire Plant)
Solidago spp. Goldenrod
Brassicaceae
**Brassica juncea* (L.) Czern. Mustard
Caprifoliaceae
Lonicera sempervirens L. Honey Suckle
Sambucus canadensis L. Elderberry
Cornaceae
Cornus florida L. Dogwood
Cyrillaceae
Cyrilla racemiflora L. Titi
Ebenaceae
Diospyros virginiana L. Persimmon
Ericaceae
Befaria racemosa Vent*.* Tarflower
Gaylussacia dumosa (Andr.) Torr. & Gray Dwarf Huckleberry
Leucothoe racemosa (L.) A. Gray Fetterbush
Lyonia lucida (Lam.) K. Koch Fetterbush
Rhododendron viscosum (L.) Torr. Azalea
Vaccinium arboreum Marsh. Sparkleberry
Vaccinium corymbosum L. Blueberry
Vaccinium myrsinites (Lam.) Shiny Blueberry ?)
Vaccinium stamineum L. Gooseberry
Euphorbiaceae
Stillingia sylvatica; Garden Queen's Root
Fabaceae
Cercis canadensis L. Red Bud
Erythrina herbacea L. Cherokee Bean, Coral Bean
Galactia elliottii Nutt. Rabbit Pea
Galactia regularis (L.) Rabbit Pea
Senna obtusifolia (L.) A.S. Irwin & Barneby Coffee Weed
Tephrosia virginiana (L.) Pers. Rabbit Pea
Fagaceae
Quercus alba L. White Oak
Quercus incana Bartr. Black Jack Oak

Quercus inopina Ashe Scrub Oak
Quercus virginiana Miller, Live Oak
Hamamelidaceae
Liquidambar styraciflua L. Sweet Gum
Juglandaceae
Carya floridana Sarg. Hickory
Carya spp. Hickory
Lamiaceae
Salvia lyrata L. Cancer Weed.
Lauraceae
Persea borbonia (L.) Sprengel, Red Bay
Sassafras albidum (Nutt.) Nees, Sassafras
Loganiaceae
Gelsemium sempervirens (L.) Ait. Yellow Jasmine
Magnoliaceae
Magnolia grandiflora L. Magnolia
Magnolia virginiana L. Magnolia (?)
Meliaceae
**Melia azedarach* L. Chinaberry
Moraceae
**Morus alba* L. Mulberry
Myricaceae
Myrica cerifera L. Bay
Myrtaceae
Eugenia confusa DC. Ironwood
Nymphaeaceae
Nymphaea odorata Ait. Pond Lily
Nuphar luteum (L.) Sibthorp & Smith Pond Lily
Oleaceae
Fraxinus spp. Ash
Orobanchaceae
Conopholis americana (L.F.) *Wallr.* Cancer Root (Cancer Weed)
Passifloraceae
Passiflora incarnata L. Passion Flower
Phytolaccaceae
Phytolacca americana L. Pokeberry
Rosaceae
Crataegus aestivalis (Walt.) T. &G. May Haw
Crataegus flava Ait. Hawthorn
Prunus sp.-Cherry
Prunus americana Marsh. Wild Plum
**Prunus persica* (L.) Batsch Peach
Prunus serotina Ehrh. Wild Cherry
Pyrus arbutiflora (L.) L.f. Chokeberry
Rubus argutus Link. Blackberry
Rutaceae
**Citrus aurantium* L. Sour Orange
Zanthoxylum coriaceum A. Rich, this is the true Prickly Ash but Z. *coriaceum* is listed as rare plant of coastal hammocks.
Zanthoxylum clava-herculis L. Prickly Ash
Sarraceniaceae
Sarracenia minor Walt. Pitcher Plant
Theaceae
Gordonia lasianthus (L.) Ellis, Loblolly Bay
Verbenaceae
Callicarpa americana L. French Mulberry
Viscaceae
Phoradendron leucarpum (Raf.) Reveal & M. C. Johnston [*P. serotinum* (Raf.) Mistletoe
Vitaceae
Vitis cinera var. *floridana* Munsony St. Augustine Grape
Vitis rotundifolia Michx. Scupernong
MAGNOLIOPHYTA – LILIOPSIDA
Amaryllidaceae
Hymenocallis palmeri S. Wats. Alligator-Lily
Arecaceae
Sabal Palmetto (Walter) Lodd. ex. Schult.
Serona repens (W. Bartram) Small Saw Palmetto
Bromeliaceae
Tillandsia usneoides (L.) L. Spanish Moss
Cyperaceae
Cladium jamaicense Crantz [*C. mariscus* (L.) Pohl subsp. *jamaicense* (Crantz) Kukenth.]. Saw Grass
Scirpus sp. Bulrush
Juncaceae
Juncus spp. Rushes
Poaceae
Andropogon virginicus L. Broomsedge
Aristida spp. Wire Grass
**Cymbopogon citratus* (DC. ex Nees) Stapf Lemongrass, Fevergrass
Panicum virgatum L. Switch Grass
Smilacaceae
Smilax laurifolia L. Maritime forests and thickets; infreq. Cat Brier
Smilax tamnoides L. Cat Brier
Typhaceae
Typha domingensis Pers. Cattail
Typha latifolia L. Cattail

References

[1]Rawlings, M.K., 1938. The Yearling. Charles Scribner's Sons, New York. 428pp.

[2]Anonymous, 1983. Climate normals for the U.S. (Base 1950-80), Volume 1. Gale Research Company, Book Tower, Detroit, Michigan. 588 pp.

[3]Fernald, M.L., 1950. Grays manual of botany. American Book Company, New York. 1632 pp.

[4]Radford, A.E., H. Ahles and C.R. Bell, 1971. Manual of the vascular flora of the Carolinas. University of North Carolina Press. Chapel Hill. NC. 1183 pp.

[5]Wunderlin, R.P., 1982. Guide to the vascular plants of central Florida. University of South Book, University Presses of Florida. Tampa. Florida. 472pp.

[6]Wunderlin, R.P., 1998. Guide to the vascular plants of Florida. University Press. Gainesville, FL 806 pp.

[7]Kartesz, J. T., 1994. A synonymized checklist of the vascular flora of the United States, Canada, and Greenland. 2nd ed. Volume 1 - Checklist. Timber Press, Inc. Portland, OR.

[8]Stalter, R., M. Leyva and D.T. Kincaid, 1999. The flora of Indian shell rings from coastal South Carolina to northern Florida. Sida 18: 861-875.

[9]Lamont, E.E. and R. Stalter, 1991. The vascular flora of Orient Beach State Park, Long Island, New York. Bull. Torr. Bot. Club **118:** 459-468.

[10]Stalter, R. and Lamont E.E., 1993. The vascular flora of Fort Sumter and Fort Moultrie, South Carolina, one year after Hurricane Hugo. Castanea **58:** 141-152.

The Human Chimeras: People With Two Types of DNA

by

Sikiru A. Fadairo

Department of Computer Information Systems
Medgar Evers College (CUNY), Brooklyn, NY

ABSTRACT

In Greek mythology, the Chimera was an awesome fire-breathing monster with the head of a lion, the body of a goat, and the tail of a serpent. The chimera was killed by the hero Bellerophon mounted, in most versions of the tale, on Pegasus, the winged horse. In biology, the term has come to refer to any organism that contains more than one set of genes. There are chimera African violets, where the core of the plant is genetically distinct from the outer layers. Animal chimeras, or mosaics, as they can also be referred to, don't usually divide so neatly. Human chimeras on the other hand, once thought to be so rare as to be just a curiosity are beginning to spark controversy among scientists as the reported cases in humans is increasing. The idea that there's a little bit of someone else in all of us and the role science is playing is discussed.

Introduction

In the TV series, CSI, a woman patient claimed that her Doctor raped her. However, the DNA taken from his blood did not match the suspect's DNA. Furthermore, the test also revealed that the most likely suspect was a relation of the Doctor. When further DNA tests cleared his relatives, the Doctor's DNA was re-tested again from a different sample, his hair. This time, the test was conclusive and it was a perfect match to the suspect's DNA. This result raises a fundamental medical question, is it possible for an individual to have two types of DNA in different parts of his/her body? Yes, geneticist have proven this fact conclusively.

Even though chimerism[1] is rare in human beings, there have been only about 50 reported cases, a chimera is a mixture of two or more different opoulations of genetically distinct cells that originate in different zygotes, in one body. In medicine, a person composed of two genetically distinct types of cells is considered a chimera. The most common form of human chimera is called a blood chimera[2]. Human chimeras were first discovered with the advent of blood typing when it was found that some had more than one blood type. This happens when fraternal twins share some portion of the same placenta, allowing blood stem cells to pass from one and settle in the marrow of the other. Each twin is genetically separate except for their blood, which has two distinct sets of genes, and two distinct blood types[3]. About 8% of fraternal twins are blood chimeras.

Chimeras are formed from four parent cells (two fertilized eggs or early embryos fused together) or from three parent cells (a fertilized egg is fused with an unfertilized egg or a fertilized egg is fused with an extra sperm). Each population of cells keeps its own character and the resulting child is a mixture of tissues[4]. Many human chimeras show no overt signs of their conditions. Others have more obvious physical features. For example, one girl was discovered to be a chimera because her eyes were different colors, one hazel, and the other brown. Others come to light when doctors investigated problems with their reproductive systems, and found that they had structures from both male and female reproductive organs as a result of having cells of both sexes in their bodies[5]. This was the

case when doctors at the University of Edinburgh in 1998 had a patient referred to them for an undescended left testicle. However, when they examined him they could not find a second testicle. Instead they found something unexpected, an ovary and a fallopian tube. Their patient was a chimera formed from the fusion of male and female embryos. While this is a dramatic finding, most chimeras show more subtle signs, such as parti-colored hair and most of them probably go through life utterly unaware of their unusual constitution.

Microchimerism

Many more people are microchimeras and carry smaller numbers of foreign blood cells that may have passed from mother across the placenta, or persist from a blood transfusions to a severely immunocompromised population of patients who suffered trauma[6]. Microchimerism is the presence of a small number of cells, genetically distinct from those of the host individual. The most common form is fetal chimerism whereby cells from a fetus pass through into the mother[7]. During pregnancy, the blood of the mother and fetus are kept separate, but some cells manage to slip through, meaning that you will have picked up some cells from your mother, and she some from you. In fact, some 80 to 90 percent of women carry their children's cells or DNA in their blood during pregnancy and up to 50 percent carry them for decades after giving birth, a condition called microchimerism[8].

The fact that fetal cells persist in mother's bloodstream for decades has been known since the mid 1990s. However, not until recently has there been serious investigations on how common it is for cells to move the other way, from mothers into their children. J. Lee Nelson, an immunologist at the Fred Hutchinson Cancer Research Center in Seattle was quoted as saying "women harbor cells from both their mother and their children"[9]. Microchimerism has been implicated in autoimmune diseases, including systemic lupus erythematosus[10,11,12]. A recent alternative hypothesis of the role microchimeric cells in lesions is that they may be facilitating tissue repair of the damaged organ[13].

Animal-Human Hybrids

Scientists have started blurring the line between human and animals by producing chimeras, a hybrid creature that's human, part animal. For example, in 2003, Chinese scientists at the Shanghai Second Medical University reportedly successfully fused human cells with rabbit eggs. The embryos were reportedly the first human-animal chimeras successfully created. After developing for several days in a laboratory dish, the scientists destroyed the embryos to harvest their stem cells[14]. In 2004, researchers at the Mayo Clinic, in Minnesota, created pigs with human blood flowing through their bodies. At Stanford University in California, Irv Weissman, director of Stanford University's Institute of Cancer/Stem Cell Biology has already created mice with brains that are about one percent human[15].

Even though animal-human hybrids sparks ethical controversy, scientists feel that the more humanlike the animal, the better research model it makes for testing drugs or possibly growing "spare parts," such as livers, to transplant into humans. They also believe that observing how human cells mature and interact in a living creature may also lead to the discoveries of new medical treatments. In 2007, scientists at the University Of Nevada School Of Medicine created a sheep that has 15% human cells and 85% animal cells[16].

Discussion

Other causes of chimerisms have been identified by researchers. For example, *In vitro* fertilization (IVF), is contributing to the number of human chimeras. IVF is a laboratory procedure in which sperm are placed with an unfertilized egg in a Petri dish to achieve fertilization. The embryo is then transferred into the uterus to begin pregnancy or cryopreserved (frozen) for future use. To

improve success rates, two or more embryos are placed in the uterus so women who have IVF have more twin pregnancies than usual. More twins mean more chimeras [17].

IVF was originally devised to permit women with damaged or absent Fallopian tubes to have a baby. Normally, a mature egg is released from the ovary (ovulated), then enters the Fallopian tube, and waits in the neck of the tube for a sperm to fertilize it. With defective Fallopian tubes, this is not possible.

One form of chimerism that is on the rise is the incidence of tetragametic chimerism. Tetragametic chimera is formed from four gametes, two eggs and two sperm. Due to their formation, they can be male, female, or hermaphroditic. Margot Kruskall, a doctor at the Beth Israel Deaconess Medical Center in Boston, Massachusetts, has ascribed this rise in tetragametic chimerism to modern fertility techniques that increases the rate of twinning. Drugs used to make a woman ovulate can cause her to release more than one egg at a time, for example, while many IVF clinics still transfer more than one embryo into the womb[18].

The fact that embryos are in close contact in the lab dish or when transferred to the womb may result in an unintended fusion, according to a report released from the University of Edinburgh in UK. In 1998, they reported a case of a chimeric IVF baby who resulted from accidental fusion of a male embryo and a female embryo. The resulting child was outwardly male, but the left hand side of his internal reproductive system had developed as an ovary and fallopian tube[19].

The tetragametic state has important implications for organ or stem-cell transplantation. Chimeras typically have immunologic tolerance to both cell lines. Hence, for a tetragametic human, a wider array of relatives and other persons may be eligible to be organ donor. Nobody knows how common tetragametic chimerism is. It has no outward signs and those who uncover their chimeric nature often do so only by accident.

Microchimerism on the other hand, had also been shown to exist after blood transfusion to a severely immunocompromised population of patients who suffered trauma. In their separate articles, published recently, Carol M. Artlett and J. Lee Nelson suggested that microchimeric cells of fetal origin may be involved in the pathogenesis of systemic sclerosis. Artlett went further to suggest that microchimeric cells of maternal origin may be involved in the pathogenesis of a group of autoimmune diseases found in children, juvenile idiopathic inflammatory myopathies (for example, juvenile dermamyositis)[20]. While microchimerism may force immunologist to re-evaluate their conclusions, it may also encouraged us to see ourselves in a new way.

Chimeras in Popular Culture

Chimeras are now appearing more frequently in popular culture. The following are among notable examples in recent time.

In the Stephen King novel, “The Dark Half’, Thad Beaumont the main character, suffers from intense migraine headaches as a child. When on the operating table, his doctors find a human eye, ear and part of a nose growing inside Thad’s skull, which was the cause of his headaches. The doctors explained this as Thad having absorbed his twin prior to birth.

The CSI: Crime Scene Investigation episode “Bloodlines” involves a man who rapes a woman and is identified by her. However, the DNA from his semen did not match the DNA from his saliva because he is a chimera.

A Discovery Health Channel special, *I Am My Own Twin,* focuses on chimeras with no outward characteristics of the trait.

A November 2006 episode of the ABC soap opera *All My Children* showed that the testing of a young character’s DNA did not turn up a match with her mother, Annie, because the character of Annie is a chimera.

A March 2008 Radio Lab episode explored the case of human chimera.

Interpreting DNA Tests[21]

In Minnesota, pigs are being born with human blood in their veins. In Nevada, there are sheep whose livers and hearts are largely human. In California, mice peer from their cages with human brain cells firing inside their skulls. These are creations of real scientists, stretching the boundaries of stem cell research. Biologists call these hybrids animal chimeras. They are the products of experiments in which human stem cells were added to developing animal fetuses.

Chimeras are allowing scientists to watch, for the first time, how nascent human cells and organs mature and interact. Some are already revealing the mysteries of human biology and pointing the way toward new medical treatments. Chimeras are not inherently unnatural; recipients of organ transplants are also chimeras, as are the many people whose defective heart valves have been replaced with those from pigs or cows. Scientists in the field of genetic engineering, for many years, have added human genes to bacteria and even to farm animals to make human proteins such as insulin for use as medicines.

Different body cells have different DNA. A DNA test is usually done by taking some blood or cheek cells and looking at the DNA. For a non-chimera, the DNA is same in every cell; however, for a chimera, it is different. Since different body cells will have different DNA, an incorrect DNA results is not uncommon for a chimera. For example, it is possible for a woman to have one set of DNA in her cheek or kidney cells and a different set of cells in her eggs. If a DNA test is performed on her children and one performed on her kidney or cheek cells, the results will be phenomenal. The results might show her as the children's aunt instead of their mother. This is the unusual results in kidney transplant and custody cases. The results often showed the children as nephews and nieces with one set of cells, and as sons and daughters with the other set of cells.

Research

A research breakthrough occurred about a decade ago when chimeras was discovered to be a resourceful research tool in a series of dramatic experiments by Evan Balaban, now at McGill University in Montreal, Canada. Balaban took a small section of brain from developing quails and transplanted them into the developing brains of chickens. The resulting chicken exhibited head bobs and vocal trill unique to quails, proving that the transplanted parts of the brain contained the neural circuitry for quail calls. It further proved that complex behaviors could be transferred across species.

The discovery of human embryonic stem cells in 1998 allowed researchers to visualize related experiments that might reveal a lot about how embryos grow. The cells, found in 5-day old human embryos, multiply prolifically and, unlike adult cells, have potential to turn into any of the body's 200 or so cell types. Scientists hope to cultivate them in laboratory dishes and grow replacement tissues for patients. However, with those applications years away, the cells are gaining in popularity for basic research.

In one on-going set of experiments, Jeffrey L. Platt[22] at the Mayo Clinic in Rochester, Minn., has created human-pig chimeras by adding human-blood-forming stem cells to pig fetuses. The resulting pigs have both pig and human blood in their vessels. Some of the cells themselves have merged, creating hybrids. The goal is to know that the risk of pig viruses getting into patient's cells is real, especially in case of transplants because the viruses may gain access when the two cells fuse.

In other experiments led by Esmail Zanjani, chairman of animal biotechnology at the University of Nevada at Reno, scientists have been adding human stem cells to sheep fetuses. The team now has sheep whose livers are up to 80 percent human, and make all the compounds human livers make. The goal is to make humanized livers available to people who need transplants. The downside, however, is that the sheep portion might be

rejected by the immune system, while the human part will take root.

Perhaps the most ambitious efforts to make use of chimeras come from Irving Weissman, director of Stanford University's Institute of Cancer/Stem Cell Biology and Medicine. He helped make the first mouse with a nearly complete human immune system, an animal that has proved invaluable for tests of new drugs against the AIDS virus, which does not infect conventional mice. More recently, his team injected human neural stem cells into mouse fetuses, creating mice whose brains are about 1 percent human. Dissecting the mice at various stages, the researchers were able to see how the added brain cells moved about as they multiplied and made connections with mouse cells. Now he wants to add human brain stem cells that have the defects that cause Parkinson's disease, Lou Gehrig's disease and other brain ailments, and study how those cells make connections.

Scientists suspect that these diseases, though they manifest themselves in adulthood, begin when something goes wrong early in development. If those errors can be found, researchers would have a much better chance of designing useful drugs and those drugs could be tested in the chimeras in ways not possible in patients.

Conclusion

In Greek mythology, a chimera was a beast made of lion, a goat and a dragon. Human chimeras are different but they actually exist. A human chimera is made up of two sets of cells with DNA as different as any two siblings' DNA. This is because a chimera is a result of fraternal twins fusing together at a very early stage in development. This can happen early during pregnancy because; embryos are made up of embryonic stem (ES) cells. At this stage, ES cells have not committed to becoming any specific kind of cell. Hence, a few additional or missing cells is well tolerated. At this stage, a cell could be removed for genetic testing (pre-implantation genetic diagnosis, PGD). Combining two sets of ES cells will create a chimera. Combining two sets of ES cells with different DNA has no consequences for the new chimera. If however, they are of different sexes, then the chimera may end up being a hermaphrodite. Unless the chimera is getting a DNA test performed, there is no way to know. While this situation definitely makes crime solving difficult, it can also complicate finding suitable organ donor.

Natural chimeras are almost never detected unless the offspring has abnormalities such as male/female or hermaphrodite characteristics or skin discoloring. Recent studies suggest that natural chimerism is far more common than previously realized and that it frequently goes undetected. Chimerism can be detected in DNA testing. The Lydia Fairchild's case, for example, was brought to court after DNA testing showed that her children could not be hers, because their DNA did not match. The charge against her was eventually dismissed because when it became clear that Lydia was a chimera, with the matching DNA being found in her cervical tissue. Another similar case was that of Karen Keegan[23].

The tetragametic state has important implications for organ or stem-cell transplantation. Chimeras typically have immunologic tolerance to both cell lines. Hence, for a tetragametic human, a wider array of relatives and other persons may be eligible to be an organ donor. Transplant doctors know that the closer the match between two people's HLA haplotypes, the lower the risk of a transplant between them being rejected. Everyone inherits two HLA haplotypes, one from each parent.

There is growing evidence that chimerism in one form or another may not be unusual at all. In fact, some researchers now think that most of us, if not all, are chimeras of one kind or another, and what was once seen as a biological oddity may serve a vital function. We may owe our lives to being chimeras.

References

[1]Chimera definition – (http://www.medterms.com).

[2]Wood, C., 2006. The Not-So-Legendary Chimera, (http://www.damninteresting.com).

[3]The Twin Inside Me: Extraordinary People Channel 5 TV, UK, March 2006. (http://www.five.tv/programmes/extraordinarypeople/twininside/)

[4]Evans, P.C., N. Lambert, S. Maloney, D.E. Furst, J.M. Moore and J.L. Nelson, 1999. Long-term fetal microchimerism in peripheral blood mononuclear cell subsets in healthy women and women with scleroderma. Blood **93(6):** 2033-2037.

[5]The Stranger Within – (http://www.katewerk.com/chimera.html)" New Scientist **180:** #2421, Nov. 2003.

[6]Reed, W., T.H. Lee, P.J. Norris, G.H. Utter and M.P. Busch, 2007. Transfusion-associated microchimerism:a new complication of blood transfusion in severely injured patients. Seminars in Hematology **44(1):** 24-31.

[7]Evans, P.C., N. Lambert, S. Maloney, D.E. Furst, J.M. Moore and J.L. Nelson, 1999. Long-term fetal microchimerism in peripheral blood mononuclear cell subsets in healthy women and women with scleroderma. Blood **93(6):** 2033-2037.

[8]Chimera.html (http://www.katewerk.com/chimera.html).

[9]Ainsworth, C., 2003. *The Stranger Within* (http://www.newscientist.com/article, (http://www.katewerk.com/chimera.html)" New Scientist 180: 2421.

[10]Johnson, K.L., T.E. McAlindon, E. Mulcahy and D.W. Bianchi, 2001. Microchimerism in female patient with systemic *lupus erythematosus*. Arthritis Rheum **44(9):** 2107-2111.

[11]Artlett, C.M., R. Ramos, S.A. Jimenez, K. Patterson, F.W. Miller and L/G Rider, 2000. Chimeric cells of maternal origin in juvenile idiopathic inflammatory myopathies. Childhood Myositis Heterogeneity Collaborative Group. Lancet **356(9248):** 2155-2156.

[12]Artlett, C.M, J.B. Smith and S.A., Jimenez, 1998. Identification of fetal DNA and cells in skin lesions from women with systemic sclerosis. New England Journal of Medicine **338(17):** 1186-1196.

[13]Gilliam, A.C., 2006. Microchimerism and skin disease: true-true unrelated?" J Invest Dermatol **126(2):** 239-241.

[14]Mott, M., 2005. Animal-Human Hybrids Spark Controversy (http://news.nationalgeographic.com/news).

[15](http://news.nationalgeographic.com/news/2005/01/0125_050125_chimeras.html).

[16](http://www.presstv.ir/detail.aspx?id=3995&sectionid=3510208).

[17]In Vitro Fertilization (IVF) definition – (http://www.medterms.com).

[18]Ainsworth, C., Nov. 2003. The Stranger Within (http://www.newscientist.com/article), (http://www.katewerk.com/chimera.html) New Scientist 180: #2421, page 34.

[19]Strain, L., J.C.C. Dean, M.P.R. Hamilton and D.T. Bonthron, 1998. A true hermaphrodite chimera resulting from embryo amalgamation after in vitro fertilization. The New England Journal of Medicine **338:** 166-169.

[20] Artlett, C.M., R. Ramos, S.A. Jimenez, K. Patterson, F.W. Miller and L.G., Rider, 2008. Chimeric cells of maternal origin in juvenile idiopathic inflammatory myopathies. Childhood Myositis Heterogeneity Collaborative Group. Lancet **356(9248):** 2155-2156.

[21]Starr, B. 2007. Human Chimeras – These Fused Fraternal Twins Can Confuse DNA Tests. (http://genetics.suite101.com/article.cfm/chimeras).

[22]Weiss, R., 2004). Chimeras – A Step Closer To Reality, (Of mice, men, and in-between). Washington Post, msnbc.com (http://www.msnbc.msn.com/id/6534243).

[23]The Twin Inside Me: Extraordinary People, Channel 5 TV, UK, March 2006, (http://www.five.tv/programmes/extraordinarypeople/twininside/).

Rodlet Cell Distribution and Activity in the Gills of Laboratory-Maintained and Wild-Caught *Fundulus heteroclitus*

by

E. Qama, J. Blaize, W.J. L'Amoreaux and C.R. Kramer
Department of Biology, College of Staten Island, Staten Island, New York 10314

Abstract

Rodlet cells were found associated with the afferent artery of the branchial skeleton of both long term laboratory-maintained and wild-caught killifish, *Fundulus heteroclitus* (L.); the latter collected from a polluted estuary. In the laboratory-maintained fish, the rodlet cells showed minimal signs of secretory activity in the form of discharged rodlets and the presence of post secretory or spent cells. Wild-caught individuals, exposed to the environmental contaminants, had a significantly greater number of rodlet cells, many of which were closely associated with the endothelium where they formed adhering junctions and were observed to be discharging their rodlets into the vascular lumen. Significantly more spent cells and a few EGCs were also present in this group. Homocellular junctions between rodlet cells were observed in the wild-caught fish, but appeared to be lacking in the laboratory maintained individuals. These observations support the role of the rodlet cell as a participant in the fish's immune response.

Key words: gills, branchial skeleton, killifish, rodlet cells

Introduction

For many years, since its initial description by Thelohan[1], the rodlet cell, found in tissues of many freshwater and saltwater teleosts[2-5], has provided a conundrum for those working in the field of fish biology. Several hypotheses have been put forth to explain the origin and function of this cell which has been most often described in the viscera and epithelium[6-13]. Over recent years, however, an increasing body of evidence has been accumulating that supports the hypothesis that the rodlet cell is endogenous and functions as an effector cell in the fish's non-specific immune response[8-10,13-22]. The reader is directed to the fine reviews of this subject by Manera and Dezfuli[22], Reite and Evensen[21] and Schmachtenberg [23].

The purpose of this study was to investigate further the purported role of the rodlet cell as an immune effector cell in the euryhaline killifish, *Fundulus heteroclitus* (L.). The distribution of rodlet cells within the vasculature of the gills of fish obtained from two different environments was compared. One group consisted of long term laboratory-maintained individuals and a second group contained fish collected from a highly polluted estuary. If the rodlet cells serve an immunological function, this should be reflected in differences in number and activity of these cells in fish from the different environments.

Materials and Methods

The former (n=17; 57.7 ± 8.9 mm in standard length, Ls (mean ± S.D.); range 44.3-69.0 mm) were obtained from a commercial supplier. No more than three fish were placed into 20-gallon aquaria containing water prepared from Instant Ocean (Carolina Biological) where they were kept for eight months. Each tank was aerated and equipped

with both undergravel and outside filters. The water chemistry was monitored daily for pH (7.3-8.1), salinity (16-24 ppt) and nitrogen levels (<1.0 ppm). A 25% water change was made every two weeks. In the interim, water and trace elements lost by evaporation were replenished. An L:D cycle of 12:12 was maintained. The fish were fed twice daily with commercial Tetramin flake food (Carolina Biological). There were no mortalities by the end of the eight month period. The wild-caught fish (n=20; 71.1 ± 7.1 mm in standard length, L_S (mean ± S.D.); range 43.5-73.0 mm) were collected during the late summer of 2007 from a highly contaminated estuary on Staten Island, New York, USA exposed to high levels of leachate and urban runoff from an adjacent landfill. Abnormally high levels of heavy metals, including Cd, Zn, Pb and Cu in addition to organic pollutants persist within the bottom sediment of the collection site[24]. Both groups contained sexually mature males and females.

The care, maintenance and sacrifice of all animals met with the approval of the IACUC (#2-N-07). All fish were sacrificed by over-anesthetizing them in a solution of MS-222 (tricaine methanesulphonate (Sigma)). Under the low magnification of a dissecting microscope, the opercular plates were carefully cut away. Individual gill arches were removed and the hemibranchs were separated and prepared for transmission electron microscopy (TEM) according to procedures previously described[11]. Sectioning was performed on a Leica Ultracut UCT ultramicrotome. Thick (1 μm) sections were stained with toluidine blue. Thin sections (80-100 nm) were collected on uncoated grids and stained with saturated aqueous uranyl acetate followed by lead citrate. Obervations were made at 80kV on a Philips CM 100 transmission electron microscope (TEM). A comparison of cell counts (Student's t-test) between the two groups was made from 10 randomly selected 1μm thick sections that contained the cartilaginous base support of the primary lamellae cut from each of 17 fish from each group. The fish from the polluted estuary on average had a greater number of rodlet cells per filament base (17.4 ± 6.5, mean ± S.D.) than those of the laboratory-maintained fish (4.45 ± 3.83, mean ± S.D.) ($P < 0.05$).

Results

Rodlet cells in abundance were observed associated with the endothelium of the afferent branchial artery in the gills of both laboratory-maintained and wild-caught *F. heteroclitus*.

In both groups of fish, distinct populations of rodlet cells forming aggregates or clusters were seen within the thin perichondrium surrounding knobs of cartilage located beneath the primary lamellae. In teleosts, this tissue forms part of the branchial skeleton which runs medially throughout the gill arch and extends vertically within the filaments to form the supportive vertical branchial rays[25]. The rodlet cells were closely associated with the endothelium of the afferent branchial artery overlying the perichondrium of each knob of cartilage (Figs. 1, 2, 3 and 4). In the laboratory-maintained fish, the rodlet cells were randomly oriented with regard to the endothelium and rarely established adhering junctions with these overlying cells (Fig. 2). Homocellular junctions between rodlet cells were not observed. Most of the cells were mature, having a basal nucleus, apical cytoplasm containing organelles including RER, well formed rodlets and a prominent fibrillar coat beneath the plasmalemma; characteristics used to define this stage[2,26]. These cells averaged 5.82 ± 1.82 μm in length and 3.76 ± 0.91 μm in width (± S.D.; n=100.). Actively secreting cells comprised 12.9% of the rodlet cell population. However, free rodlets, either in the vascular space or surrounding tissue elements were never observed. Spent cells made up 5.3% of the cell population.

The rodlet cells of the wild-caught fish for the most part were normal in appearance, resembling those of the laboratory group. Again, mature cells were most numerous. The length (5.58 ±1.32 μm) and width (3.45 ± 1.58 μm) (mean ± S.D.) of the cells as well as

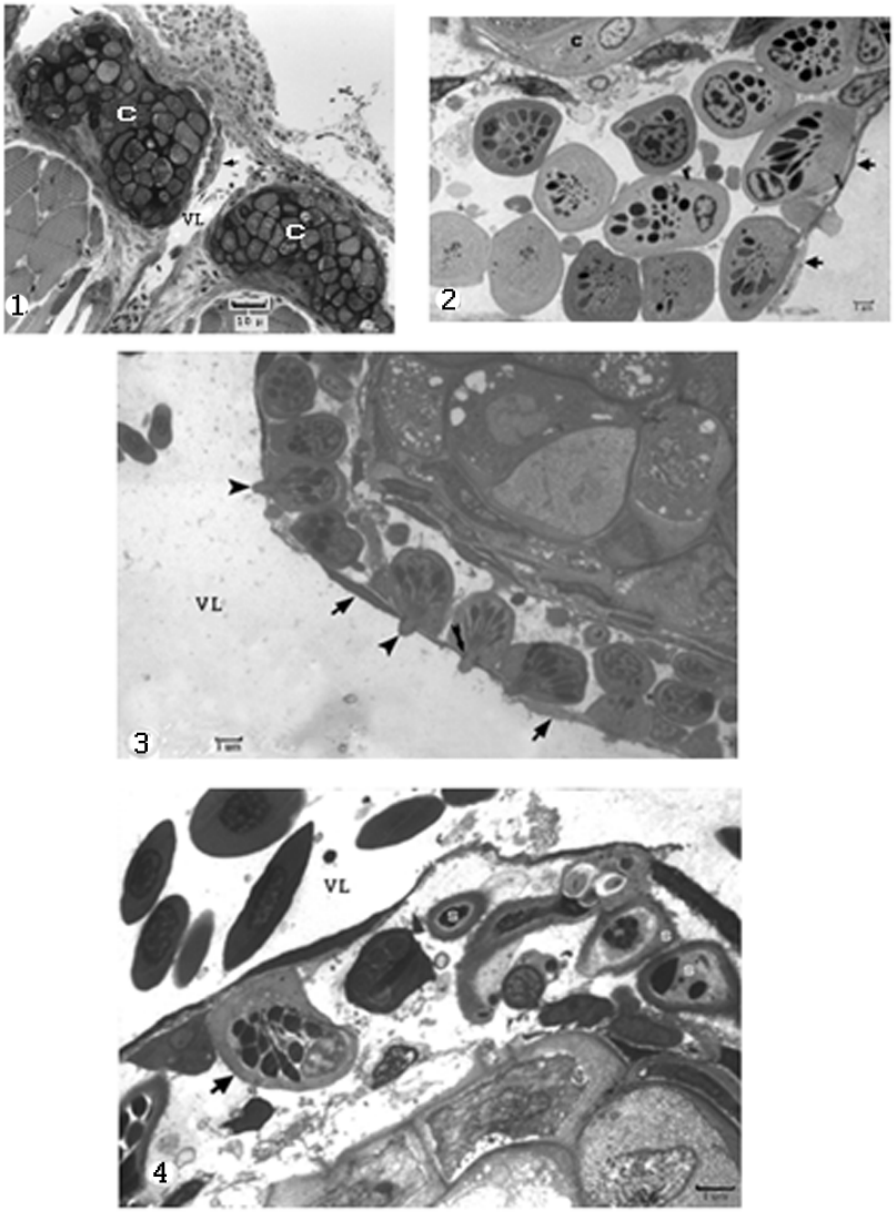

Fig.1. A thick epon section through the hemibranch of the gill of a laboratory-maintained *Fundulus heteroclitus* containing knobs of hyaline cartilage (C) that are part of the branchial skeleton. Rodlet cells (◄—) can be seen within the perichondrium and underlying the lumen (VL) of the afferent branchial artery that services the filament. Toluidine blue; x 375.

Fig. 2. Mature rodlet cells randomly oriented within the perichondrium and beneath the endothelium (◄—) of a laboratory-maintained *F. heteroclitus*; chondrocyte (C). (TEM). x 2600.

Fig. 3. Numerous mature rodlet cells oriented perpendicular to the afferent branchial artery of a wild-caught *F. heteroclitus*. Note, many of them are secreting (►) between the endothelial cells (→►) into the vascular lumen (VL). Apical adhering junctions are visible between the rodlet cell and epithelium (➡). TEM. x 1450.

Fig. 4. A wild-caught *F. heteroclitus*, showing several spent rodlet cells (S). A mature rodlet cell (→►) is seen closely apposed to the overlying endothelium; vascular lumen (VL). TEM. x 2600.

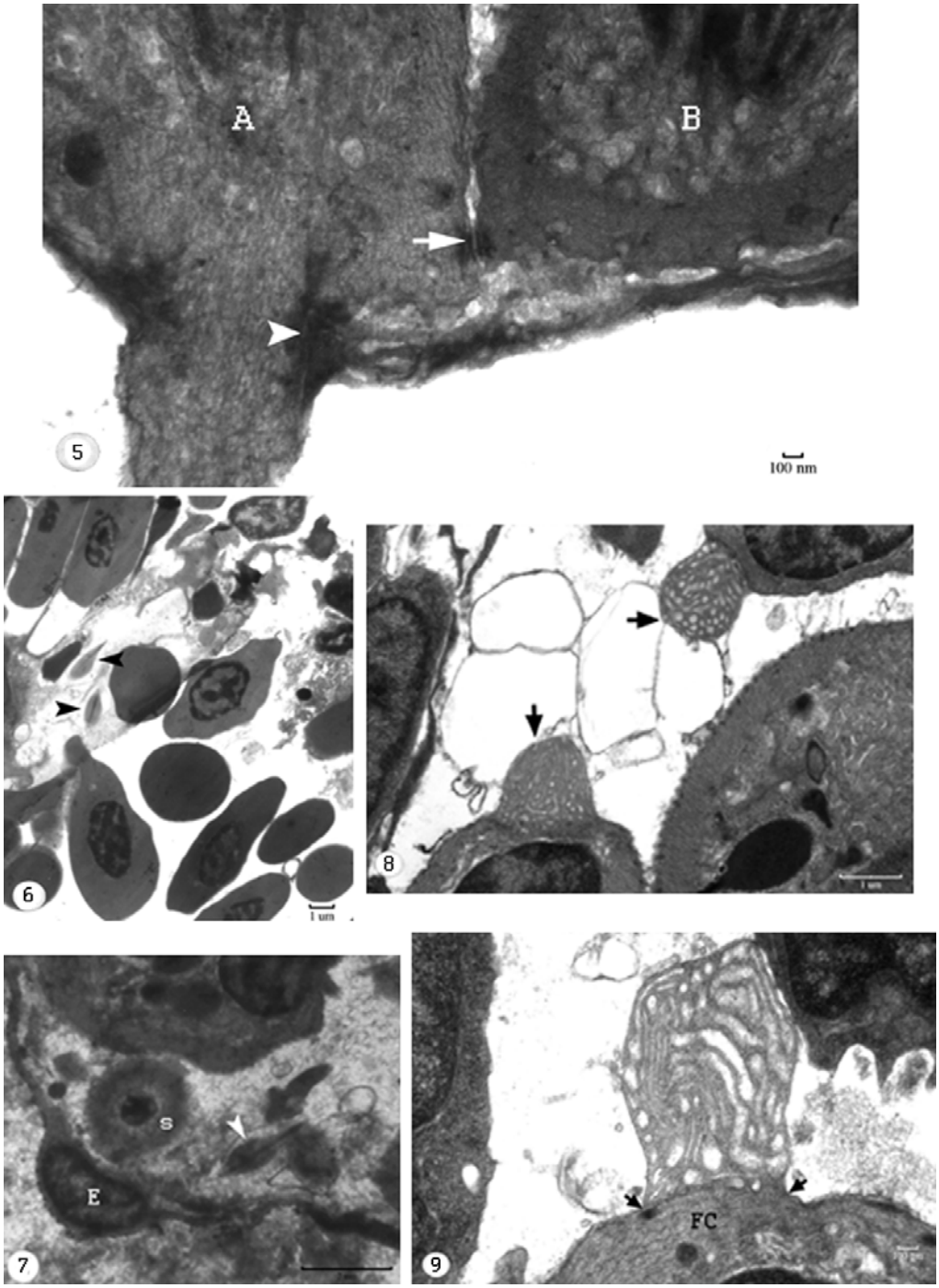

Fig. 5. Two mature rodlet cells of a wild-caught *F. heteroclitus.* Cell A can be seen secreting into the vascular lumen and has formed a tight junction with the endothelial cell (►). A homocellular junction in a form of a desmosome (→) exists between cells A and B. TEM. x 19,000.

Fig. 6. Discharged rodlets (►) found in the blood of a wild-caught *F. heteroclitus.* The dense central core is visible. TEM. x 3400.

Fig. 7. A discharged rodlet (►) within the subvascular elements of the afferent branchial artery of a wild-caught *F. heteroclitus.* An overlying endothelial cell (E) and spent rodlet cell (S) are apparent. TEM. x 4600.

Fig. 8.Two mature rodlet cells in the subvascular tissue of a wild-caught *F. heteroclitus* with an apparent marked bleb or blister (→) containing SER-like membrane in the form of a labyrinth. TEM. x 10,500.

Fig. 9. A higher magnification of a mature rodlet cell, different from those represented in Fig. 8, showing the marked bleb. Note, the plasmalemma (→) appears to be continuous and the fibrous coat (FC) is still intact. TEM. x 25,000.

the rodlets themselves, appeared to be unaffected by exposure to the environmental contaminants. In contrast to the laboratory-maintained fish, the wild-caught individuals exposed to the contaminants showed several marked differences. The majority of the rodlet cells were oriented perpendicular to the vascular lumen and adhering junctions, e.g., desmosomes and tight junctions were formed between the apical ends of the cells and the endothelial cells (Figs. 3 and 5). Unlike the laboratory fish, homocellular adhering junctions in the form of desmosomes were observed between the rodlet cells of the wild fish (Fig. 5). Although this is the first time we have observed junctions between rodlet cells such attachments have previously been reported in the goldfish, *Carassius auratus* (L.)[20]. Many of the rodlet cells (33.7 %) were in an active state of secretion as evidenced by the protrusion of the cellular apices between the endothelial cells and into the vascular lumen, the presence of discharged rodlets both within the vascular space and among the tissue elements and the large number of spent cells (12.7%) that had presumably released their rodlets and became apoptotic (Figs. 3, 4, 6 and 7). The number of secreting and spent cells in the wild-caught group was significantly greater than the same cell populations in the laboratory-maintained fish ($P< 0.01$ and $P< 0.05$ respectively). The discharged rodlets appeared to remain intact. Schmachtenberg[23], recently observed that free discharged rodlets from rodlet cells obtained from dissociated olfactory epithelium of the grunt, *Isacia conceptionis*[24] (Cuvier 1830), remained visually intact for up to 12 h. We never observed free rodlet cells within the blood. Intact EGCs (2%) were also present within the sub vascular tissue of the wild-caught fish. EGCs, the purported analog of the mammalian mast cell[21], appear to be recruited to sites of tissue damage where they release specific mediators of the inflammatory response[21]. This is a general response in teleosts. Furthermore, in some species, EGCs have been observed to be co-recruited with rodlet cells to sites of parasite-induced inflammation providing evidence that both cells function in the fish's defense system whereby EGCs specifically act within the connective tissue elements while the rodlet cells perform a similar function for epithelial tissue[15]. According to Reite[15], these cells could act independently or co-dependently which would explain variations in their activity and distribution in different species.

The EGCs that we observed in the sub-vascular connective tissue of the wild-caught fish had not degranulated. This coincided with the lack of any signs of inflammation or necrosis. Although the number of EGCs was low in the wild fish, their relative absence (12 cells were counted in a total of 170 sections observed) in the laboratory-maintained group indicates that their appearance in the former was a response to some immunological trigger, presumably one or more of the contaminants to which the fish were exposed. The greater number of rodlet cells relative to EGCs suggests that the overlying endothelium, which was more directly exposed to the environmental toxins than the subvascular tissue, was protected by a first line of defense, the rodlet cells. The pollutants had not yet penetrated or not sufficiently so to mobilize the EGCs fully, including their degranulation.

Interestingly, several (n=12) mature rodlet cells in the wild fish had a conspicuous bleb or blister that appeared to extend from the basal plasmalemma immediately beneath the nucleus (Fig. 8). Close examination revealed what appeared to be an SER-like membranous structure in the form of a labyrinth contained within this cytoplasmic extension. The fibrillar layer underlying the extension was still intact, however. Similar structures have been reported in rodlet cells, but were described as being much smaller and lacking the SER-like component[3,11]. Also, in these studies, the fibrillar coat was absent in the region underlying the extension. According to Barber *et al.*[3], the small outpocket probably served a nutritive function.

One interpretation of the evaginated surface that we observed is that it was part of a neighboring cell whose membrane was closely apposed to that of the rodlet cell. Three points lead us to reject this conclusion: (1) rodlet cells with the protrusion had this identical structure located in the same region of the cell (2) at higher magnification, the membrane of the rodlet cell could be seen extending outward away from the cell forming what appeared to be a continuous wrapping around the presumptive SER (?) (Fig. 9) and (3) any signs of membrane to membrane adhesion such as tight junctions or desmosomes that would indicate attachment to neighboring cells, were lacking. We suggest that, more probably, the bleb represented a cellular pathology induced by one or more of the pollutants to which the fish were exposed. This interpretation is supported by a number of recent studies that have shown cytopathological effects of environmental contaminants on the structure of rodlet cells in various organs including those found in the gills[27,28,29]. These pathologies included cell degeneration, cytoplasmic vacuolization, appearance of myelinoid-like figures within the cytoplasm and mitochondrial degeneration[30].

Although the primary and secondary lamellae were not the focus of this study, mature rodlet cells were observed within the former. In both groups of fish, these cells appeared to be normal. A few immature cells were present.

Discussion

The constant exposure of gills to a changing aquatic environment presents a potential portal through which microbes, parasites, toxins and other noxious agents can exert their effects on the behavior and physiology of fishes. Ostensibly, in order to meet this challenge the branchial components must be equipped with an immunological barrier that most likely includes the rodlet cells. Several studies have provided evidence that the rodlet cells are active participants in the immune response of the gills. Dezfuli *et al.*[16] observed an increase in the number of rodlet cells in the primary and secondary lamellae of the gills of the bream, *Abramis brama* (L.) infected with the copepod *Ergasilus sieboldi.* Likewise, Mazon *et al*.[31] recently found that rodlet cells increased in number in parasite-infected gills of *Cyprinus carpio* L. A similar effect was observed in the gills of the chub, *Leuciscus cephalus* (L.) when exposed to the herbicide propanil[17]. Increased activity of the rodlet cells was also reported in the gills of the European sea bass, *Dicentrarchis labrax* (L.) subjected to osmotic shock[27].

These findings support the role of the rodlet cells as immune effector cells in the gill of *F. heteroclitus.* Our observations show that in *F. heteroclitus* the rodlet cells were localized in an area of the branchial skeleton where they were in close proximity to the blood which would enable these cells to deposit their secretions quickly into the vascular flow when it becomes necessary. The increase in number and activity of the rodlet cells and the release of their rodlets into the blood of the wild-caught fish that were exposed to pollutants supports this claim. Furthermore, the close anatomical connection between the afferent branchial artery and the central venous sinus of the filament could provide a conduit whereby the rodlet cells would service other parts of the branchium. In addition, this area could serve as a storage site from which rodlet cells can be recruited by other gill components.

Acknowledgments

This study was supported by a PSC-CUNY research grant (#68026-0037) to CRK. We are grateful to Ms. Marie Caroline Martin, student in the EEB program at the CUNY Graduate School, for her French translation.

References

[1]Thelohan, P., 1892. Sur des sporozoaires indetermines parasites des poissons. J. Anat. Physiol. Paris, **28:** 163-171.

[2]Leino, R.L., 1974. Ultrastructure of immature, developing and secretory rodlet cells in fish. Cell Tissue Res. **155(3):** 367-381.

[3]Barber, D.L., J.E. Mills Westermann and D.D. Jensen, 1979. New observations on the rodlet cell (*Rhabdospora thelohani*) in the white sucker, *Catastomas commersoni*: LM and EM studies. J. Fish Biol. **14(3):** 277-284.

[4]Mayberry, L.F., A.A. Marchiando, J.E Ubelaker and D. Kazic, 1979. *Rhabdospora thelohani* Laguesse', 1895 (Apicomplexa): new host and geographic records with taxonomic considerations. J. Protozool. **26(2):** 168-178**.**

[5]Bielek, E. and G. Viehberger, 1983. New aspects on the "Rodlet Cell" in teleosts. J. Submicrosc. Cytol*.* **15(3):** 681-694*.*

[6]Smith, S.A., T. Caceci, HE-S Marei and H.A. El-Habback, 1995. Observations on rodlet cells found in the vascular system and extravascular space of angelfish, *Pterophyllum scalare scalare*. J. Fish Biol. **46(2):** 241-254.

[7]Smith, S.A., T. Caceci and J.L. Robertson, 1995. Occurrence of rodlet cells and associated lesions in the vascular system of freshwater angelfish. J. Aquat. Anim. Health, **7(1):** 63-69.

[8]Leino, R.L., 1996. Reaction of rodlet cells to a myxosporean infection in the kidney of the bluegill, *Lepomis machrochirus.* Can. J. Zool. **74(2):** 217-225.

[9]Dezfuli, B.S., S. Capuano and M. Manera, 1998. A description of rodlet cells from the alimentary canal of *Anguilla anguilla* and their relationship with parasitic helminths. J. Fish Biol. **53(5):** 1084-1095.

[10]Dezfuli, B.S., E. Simoni, R. Rossi and M. Manera, 2000. Rodlet cells and other inflammatory cells of *Phoxinus phoxinus* infected with *Raphidascaris acus* (Nematoda). Dis. Aquat. Org. **43(1):** 61-69.

[11]Kramer, C.R. and H. Potter, 2002. Ultrastructural observations on rodlet-cell development in the head kidney of the southern platyfish, *Xiphophorus maculatus* (Teleostei: Poeciliidae). Can. J. Zool. **80 (8):** 1422-1436.

[12]Kramer, C.R. and H. Potter, 2003. Rodlet cells in the posterior intestine of embryos and neonates of two poeciliid species. J. Fish Biol*.* **62(5):** 1211-1216.

[13]Kramer, C.R., A. Kramer and A. Konovalov, 2005. Rodlet cell distribution in the gall bladder epithelium of *Fundulus heteroclitus*. J. Fish Biol. **67(2):** 555-560.

[14]Reite, O.B., 1997. Mast cells/eosinophilic granule cells of salmonids: staining properties and responses to noxious agents. Fish Shellfish Immunol*.* **7(8):** 567-584.

[15]Reite, O.B., 2005. The rodlet cells of teleostean fish: their potential role in host defence in relation to the role of mast cells/ eosinophilic granule cells. Fish Shellfish Immunol*.* **19(3):** 253-267.

[16]Dezfuli, B.S., L. Giari, R. Konecny, R. Jaeger and M. Manera, 2003. Immunocytochemistry, ultrastructure and pathology of gills of *Abramis brama* from Lake Mondsee, Austria, infected with *Ergasilus sieboldi* (Copepoda). Dis. Aquat. Org. **53(3):** 257-262.

[17]Dezfuli, B.S., L. Giari, E. Simoni, D. Palazzi and M. Manera, 2003. Alteration of rodlet cells in chub caused by the herbicide Stam® M-4 (Propanil). J. Fish Biol. **63(1):** 232-239.

[18]Dezfuli, B.S., L. Giari and A.P. Shinn, 2007. The role of the rodlet cells in the inflammatory response in *Phoxinus phoxinus* brains infected with *Diplostomum*. Fish Shellfish Immunol. **23 (2):** 300-304.

[19]Abraham, M., Y. Iger and L. Zhang, 2001. Fine structure of the skin cells of stenohaline freshwater fish *Cyprinus carpio* exposed to diluted seawater. Tissue Cell **33(1):** 46-54.

[20]Manera, M., E. Simoni and B.S. Dezfuli, 2001. The effect of dexamethasone on the occurrence and ultrastructure of rodlet cells in goldfish. J. Fish Biol. **59(5):** 1239-1248.

[21]Reite, O.B. and O. Evensen, 2006. Inflammatory cells of teleostean fish: A review focusing on mast cells/eosinophilic granule cells and rodlet cells. Fish Shellfish Immunol. **20(2):** 192-208.

[22]Manera, M. and B.S. Dezfuli, 2004. Rodlet cells in teleosts: a new insight into their nature and functions. J. Fish Biol. **65(3):** 597-619.

[23]Schmachtenberg, O., 2007. Epithelial sentinels or protozoan parasites? Studies on isolated rodlet cells on the 100th anniversary of an enigma. Rev. Chil. Hist. Nat. **80(1):** 55-62.

[24]Perez, M.H. and W. Wallace, 2004. Differences in prey capture in grass shrimp, *Palaemonetes pugio*, collected along an environmental impact gradient. Archiv. Environ. Contam. Toxicol. **46(1):** 81-89.

[25]Wilson, J.W. and P. Laurent, 2002. Fish gill morphology: Inside out. J. Exp. Zool. **293 (3):** 192-213.

[26]Mattey, D.L., M. Morgan and D.E. Wright, 1979. Distribution and development of rodlet cells in the gills and pseudobranch of the bass, *Dicentrarchis labrax*. J. Fish Biol. **15(3):** 363-370.

[27]Giari, L., M. Manera, E. Simoni and B.S. Dezfuli, 2006. Changes to chloride and rodlet cells in gills, kidney and intestine of Dicentrarchis labrax (L.) exposed to reduced salinities. J. Fish Biol. **69(2):** 590-600.

[28]Giari, L., M. Manera, E. Simoni and B.S. Dezfuli, 2007. Cellular alterations in different organs of European sea bass *Dicentrarchis labrax* (L.) exposed to cadmium. Chemosphere, **67(6):** 1171-1181.

[29]Giari, L., E. Simoni, M. Manera and B.S. Dezfuli, 2008. Histo-cytological responses of *Dicentrarchis labrax* (L.) following mercury exposure. Ecotoxicol. Environ. Saf. 70(3): 400-410.

[30]Dezfuli, B.S., E. Simoni, L. Giari, L. and M. Manera, 2006. Effects of experimental terbuthylazine exposure on the cells of *Dicentrarchis labrax* (L.). Chemosphere, **64(10):** 1684-1694.

[31]Mazon, AF., M.O Huising, A.J. Taverne-Thiele, J. Bastiaans, and B.M.L. Verburg-van Kemenade, 2007. The first appearance of rodlet cells in carp (*Cyprinus carpio* L.) ontogeny and their possible roles during stress and parasite infection. Fish Shellfish Immunol. **22(1-2):** 27-37.

Teratogenic Effects of Lithium Chloride on Eye Development in Early Embryogenesis of Zebrafish (*Danio rerio*)

Christina M. Lamb, Ammini S. Moorthy, Christopher P. Corbo and Zoltan L. Fulop

Department of Biological Sciences, Wagner College, Staten Island, NY

Abstract

This study is focused on the teratogenic effects of lithium chloride (LiCl) on zebrafish (*Danio rerio*) eye development from a morphological perspective. In order to explore the effects of LiCl on the morphology of developing zebrafish embryos, a blind study was performed with the embryos being exposed to 0.15 M, 0.30 M and 0.45 M LiCl in the water while the control group had no LiCl in their water. Using light and scanning electron microscopy, defects were viewed. Embryos exposed to 0.15 M LiCl showed defects in eye development to different degrees including lateral delay in eye formation, irregular eye shape and the loss of one eye. All embryos exposed to 0.30 M LiCl failed to develop eyes altogether. Scanning electron micrographs of the 0.30 M LiCl exposure group not only displayed somewhat developed skulls but also a complete lack of eye formation. All embryos exposed to 0.45 M LiCl died.

Introduction

Clinical trails have concluded that lithium chloride (LiCl) should be considered a key drug to treat acute depression caused by bipolar disorder[1] in humans. Although its use as a treatment option has been generally supported, the use of LiCl must be avoided in pregnant women who suffer from bipolar disorder because it has shown teratogenic effects in early pregnancy[2]. Currently, the mechanism of lithium chloride's action remains unclear, so continued research is warranted.

During the last decades, the zebrafish (*Danio rerio)* has become an important vertebrate animal in developmental research. Because of the transparency of the chorion and simplicity of chemical exposure in the aquatic environment, the zebrafish is a useful model animal in developmental toxicology. In studies with zebrafish embryos, exposure to LiCl caused defects in anterior-posterior development; and abnormal eye and tail development were noted with escalating severity with increased lithium chloride concentrations[3]. Lithium chloride has been shown to affect zebrafish development during two specific phases, and these two phases corresponded to separate defect patterning found in the embryos[4]. The first phase of LiCl effect is the initial entry of the chemical at the 16-cell stage. Embryos exposed in these early stages of development (before the mid-blastula stage) develop radialized defects. The embryos appear twisted above the yolk and the notochord cells become stacked while normal embryos have distinct notochord regions separated by yolk[4]. The second phase occurs after the midblastula stage. Embryos exposed at this stage and prior to early gastrulation display anterior-posterior deficiency, eye and head defects[4]. As noted above, previous research has revealed defects in anterior posterior development in zebrafish embryos exposed to LiCl[3], but no histological analysis has yet been performed on such defects. The aim of this study is to analyze the teratogenic effects of LiCl during early development of zebrafish using light and scanning electron microscopy.

Materials and Methods

Zebrafish Breeding

For breeding, adult zebrafish obtained from a local pet store were housed in a temperature controlled (28°C) breeding colony room on a 14h: 10h light cycle. Tanks were inspected daily for water temperature, salinity, and water level and filters were changed approximately every two months. Fish were fed TetraMin® flake food once a day on non-breeding days and three times on the day before breeding. Breeding fish were also supplemented with brine shrimp (*Artemia franciscana*) along with the flake food, to supply breeding fish with additional protein. Fish were bred in modified commercially available breeding boxes. For additional information concerning care and breeding of adult zebrafish please refer to Westerfield[5] or contact the authors.

Collection and Care of zebrafish embryos

Twelve zebrafish eggs were transferred from the breeding boxes to 250 ml beakers filled with 100 ml of egg water (1.5 ml stock salt/1000 ml deionized water [stock salt- 40g Instant Ocean®/1000 ml de-ionized water]). Embryos hatched around day three post fertilization. Fry were fed 2 ml of *Paramecium* culture[5] twice a day up to 10 days. Fish were transferred daily to a new beaker of fresh egg water using a plastic transfer pipette. All beakers were kept in a water bath at approximately 28°C to ensure proper growth and hatching times.

Lithium Chloride Exposure

The LiCl experiment was performed blind, only the PI knew the actual concentrations of the solutions used in this experiment which were labeled as A, B, C, and D, -- 0.45 M, 0.30 M, 0.15 M, and a 0.0 M, respectively. Information from J. White[3] was used as a basis for concentration selection. One-day-old embryos were transferred to appropriate beakers and exposed for 10 min. Embryos were then removed and washed twice in egg water for another 10 min. Embryos were allowed to develop, and were monitored and photographed daily to view morphological changes.

Histotechniques

On day 10 post fertilization, surviving fry were killed by Tricaine overdose and fixed with Karnovsky's fixative[6] at 4°C overnight. Fixed specimens were washed twice with phosphate buffer (PB) for 10 min each. Specimens were then post fixed in 1% osmium tetroxide for 30 min at room temperature. Osmium was removed by rinsing 5 min in PB and the embryos were dehydrated through increasing concentrations of ethanol (50%, 70%, 80%, 95%, 100%, 100%) for 10 min each. Some specimens were processed for semi-thin sectioning, while others were prepared for scanning electron microscopy.

Specimens reserved for light microscopy were treated with propylene oxide twice for 15 min each then infiltrated and embedded with Spurr medium[7]. The Spurr medium was polymerized overnight at 60°C. Semi-thin (1 µm) sections were cut using a Reichert OM-1 ultramicrotome with glass knives. Slides were stained with 1% tolludine blue, coverslipped and photographed using an Olympus BX40 microscope with a Sony ExWave HAD digital camera.

Scanning Electron Microscopy

After ethanol dehydration, the specimens designated for scanning electron microscopy were fully dried through evaporation with Hexamethyldisilazane (HMDS) and were mounted on aluminum stubs using carbon adhesive, coated in gold using the Hummer VI Sputtering System and photographed using a Topcon ABT-32 scanning electron microscope.

Results

Control fish developed normally and showed no deformation (Figure 1). Fish were active in beakers and avoided the transfer pipette during cleaning, a normal behavior of zebrafish fry.

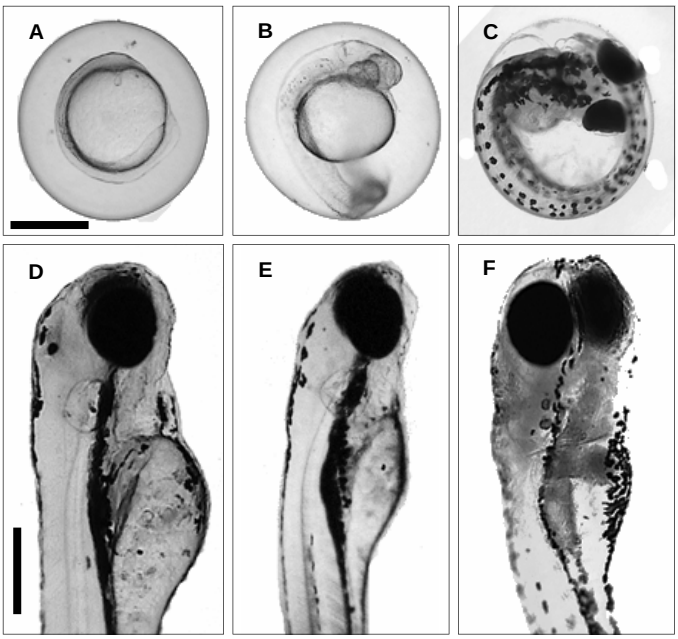

Fig. 1: Stages of normal zebrafish development: A. Day 1; B. Day 2; C. Day 3; D. Day 4; E. Day 5; F. Day 10. Scale bars are 100 micrometer each. Note: the pigmentation of the eye begins at day 3 and the eyes seemingly do not change in size up until day 10.

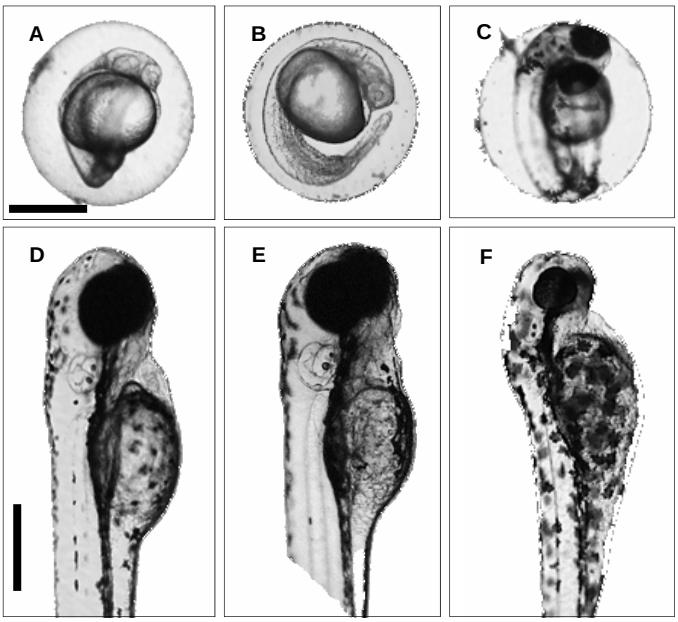

Fig. 2: Stages of zebrafish development after exposure to 0.15M Lithium chloride: A. Day 1; B. Day 2; C. Day 3; D. Day 4; E. Day 5; F. Day 10. Scale bars are 100 micrometer each. Note: Eye pigmentation begins at day 3, similar as in the control, however, the size of the eyes at day 10 are seemingly smaller as compared to the control.

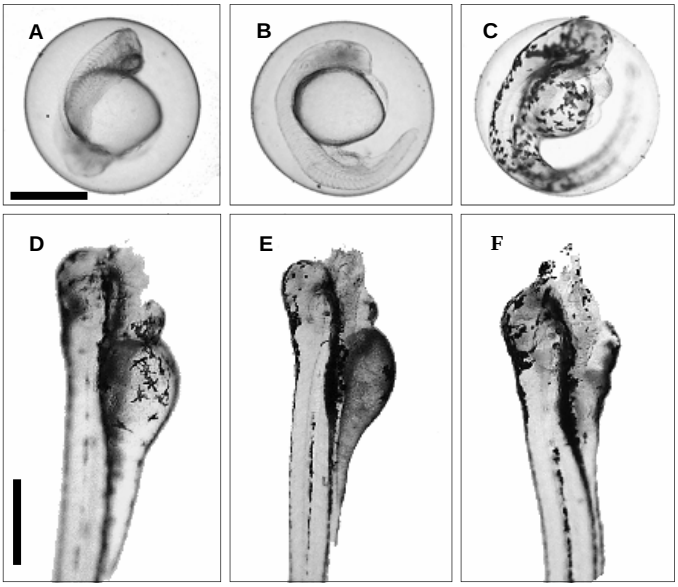

Fig. 3: Stages of zebrafish development after exposure to 0.30M Lithium chloride: A. Day 1; B. Day 2; C. Day 3; D. Day 4; E. Day 5; F. Day 10. Scale bars are 100 micrometer each. Note: Eye begins to form at day 1, but stops to develop further and actually begins to deteriorate as early as day 2. At day 3, the general pigmentation of the fish begins as in the normal fish, but no eyes can be seen. The entire head region begins to deteriorate by day 4 reaching its peak by day 10.

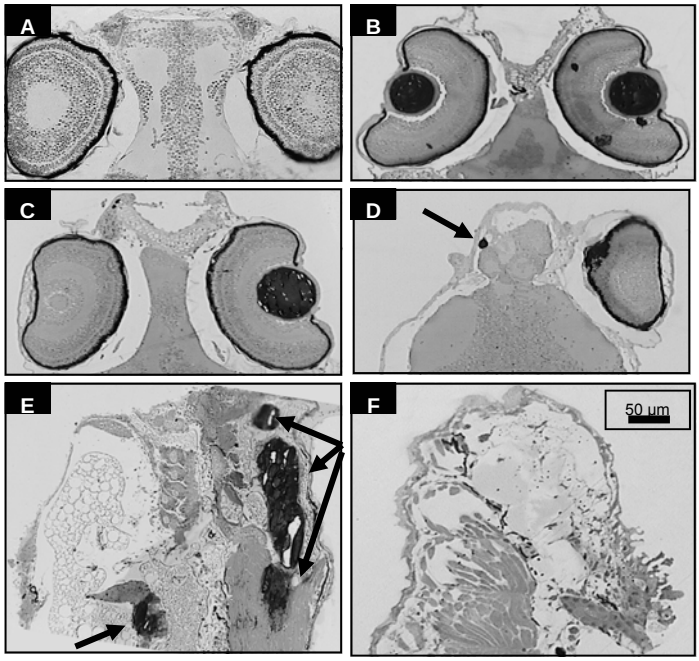

Fig. 4: Photomicrographs A and B depict normal embryonic zebrafish head region as seen in semithin (1 µm) sections stained with toludine blue under the light microscope. A. Day 4; B. Day 10. Note: The cellular layers are already formed by day 4, but the lens is not developed until day 10 (the lens looks dark because it is heavily stained by the toludine blue). Photomicrographs C and D depicts development after exposure to 0.15M Lithium chloride at day 10 of development. Note the uneven development of the eyes, especially the lens when comparing the two eyes (C). However, in some cases, one eye would not develop completely (arrow), while the other eye, although apparent, had easily recognizable signs of mal-development (D). Photomicrographs E and F depict development after exposure to 0.30M Lithium chloride at day 10 of development. Note some deformed tissue masses enriched with pigmented cells (arrows) at the location where the eyes should have developed (E). In other cases, (F), the eyes did not develop at all. The scale bar is for all the depicted micrographs.

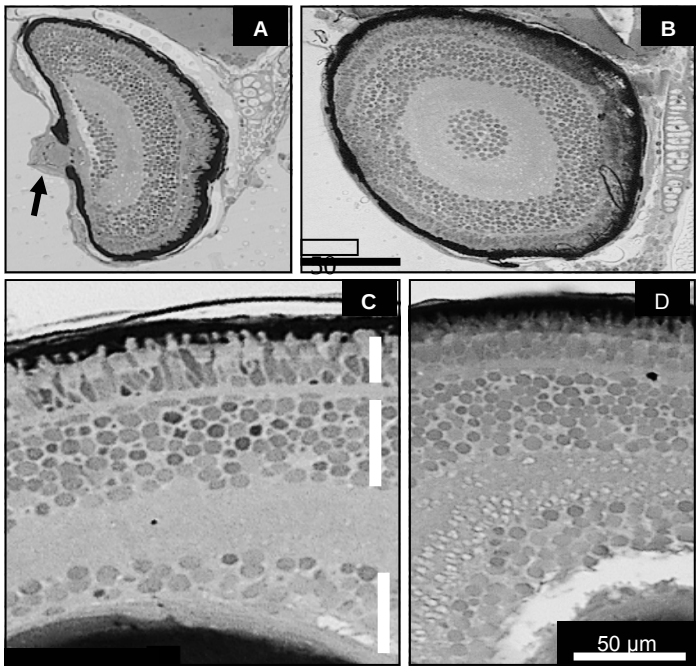

Fig. 5: Photomicrographs A and B depict normal embryonic zebrafish eyes as seen in semithin (1 µm) sections stained with toludine blue under the light microscope. Photomicrograph A—horizontal section (arrows points toward forming lens), while B is a sagittal section of the eye. Photomicrograph C depicts the layers of the developing retina of normal 10-day-old embryonic eye. Photomicrograph (D) - the 10-day-old developing retina after exposure to 0.15M Lithium chloride. Note: Layers of the retina from the top downward in (C) are: (1) the dark line above the first white vertical line is the pigmented epithelial layer; (2) the first white vertical line points to the layer of photo sensory cells (rods and cones); (3) between the first and second vertical white line is the external plexiform layer; (4) the second white line depicts the layer of bipolar and horizontal cells; (5) below the second line in the inner plexiform layer; (6) the third white vertical line depicts the granular layer, (7) and below this layer the white matter formed by the axons of the ganglionic cells. (8) The black spot is the heavily stained lens portion. Photomicrograph D shows that all of the layers of the retina are present in a eye developing under 0.15M, however, the level of the differentiation of the photo sensory cells are lagging behind the normal and in the inner plexiform layer, shows signs of spongiform degeneration. (The white region below the ganglionic layer is an artifact). Scale bars for A and B and for C and D are the same, respectively.

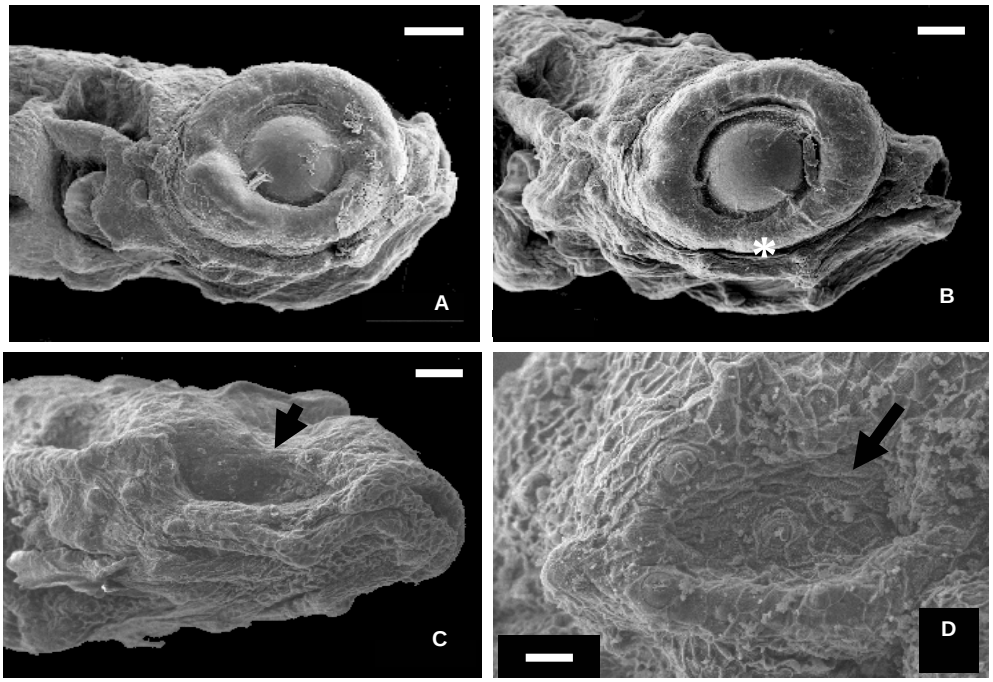

Fig. 6: Scanning electron micrographs of 10-day-old normal zebrafish embryo's head region (A) and that of developing after exposure to 0.15M (B) and 0.30M Lithium Chloride (C), respectively. Electron micrograph D depicts an eye region of a 10-day-old zebrafish embryonic head developing after 0.30M Lithium Chloride . Note in micrograph B, the asterisk points to a thinner, maldeveloped region on an otherwise normal looking eye formation. Fish developing in 0.3M Lithium Chloride did not develop eyes. Micrograph C and D depicts such an example. Arrows point to the region where the eye should have developed. For orientation, the mouth of the fish is in the right side of our images. Scale bars are different and labeled on each image. Scale Bars on micrographs A, B & C D 50 µm, 36 µm, 20 µm, respectively.

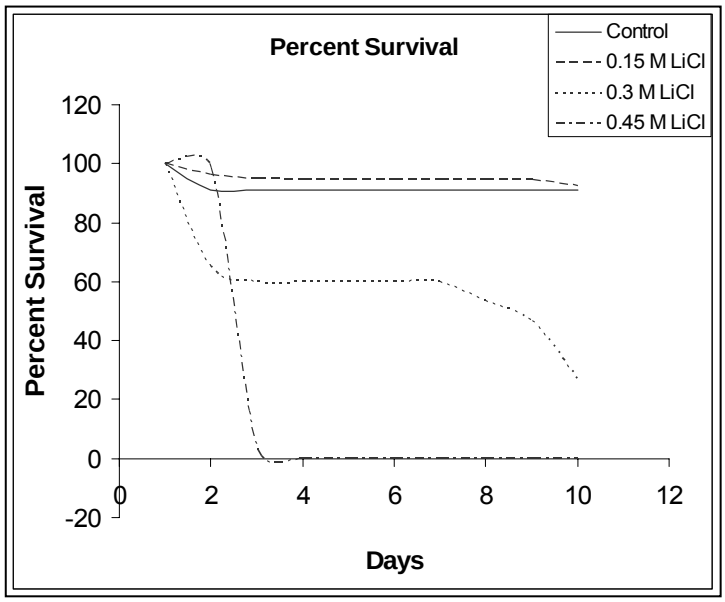

Fig. 7: Graph of zebrafish survival over ten day time course. Percent Survival is shown for all groups.

Table 1. Fisher's Exact Probability Test for Embryos Exposed to Lithium Chloride

	0.15 M LiCl	Control	Total
Die	4	4	8
Live	49	40	89
Total	53	44	97

P Value = 0.533681, α level = 0.017

	0.30M LiCl	Control	Total
Die	11	4	15
Live	4	40	44
Total	15	44	59

P Value = 4.646×10^{-6}, α level = 0.017

	0.45M LiCl	Control	Total
Die	30	4	34
Live	0	40	40
Total	30	44	73

P Value = 4.646×10^{-6}, α level = 0.017

Zebrafish exposed to 0.15 M LiCl showed a variety of eye defects including small and irregularly shaped eyes (Figure 2F). Occasionally, bilateral asymmetry of the eye development could be observed (Figure 4C) while in other cases only one eye developed (Figure 4D). Despite the occurrence of developmental defects, fry exhibited normal behavior such as actively avoiding the transfer pipette, energetically eating during feeding times, and constantly swimming in beakers. Zebrafish exposed to 0.30 M LiCl failed to develop eyes in all of the 58 cases studied (Figures 3 & 4 E,F). Not only did fish fail to develop eyes, but their behavior was also abnormal. Fish remained sedentary and exhibited almost no swimming or dodging movement when transferred in a pipette. Many embryos did not survive past day 2 (Figure 7 and Table 1), and a large portion of fish did not hatch throughout the 10-day time period. Fish that did hatch did not display normal feeding behavior. Although normal feeding behavior was not seen, several fish survived until day 10.

Zebrafish exposed to 0.45 M LiCl did not hatch and eggs appeared clouded within 24 h. No images exist for this exposure group.

Light microscopy of semithin sections revealed the cellular organization of the eye. Control fish displayed normal cellular organization (Figures 4 A, B & 5 A, B, C). Fry exposed to 0.15 M LiCl appeared to have a variation of eye defects, bilateral asymmetry and development of only one eye (Figures 4 C,D). Eyes that did develop showed normal patterning and layering (Figures 5D). Fry exposed to 0.30 M lacked normal eye tissue (Figure 3).

Scanning electron microscopy of control specimens (Figure 6A), specimens exposed to 0.15 M LiCl (Figure 6B), and specimens exposed to 0.30 M LiCl (Figures 6 C,D), revealed a slight difference in eye shape between control and 0.15 M LiCl-exposed fry. Eyes of fish exposed to 0.15M LiCl showed only slight malformation (Figure 6B asterisk). The inferior edge of the rim of the eye looks smaller than in the control. The 0.30 M LiCl exposure group displayed a complete lack of eye formation. The head region, including the eye socket appears as a scale covered indention where the eye was expected to develop (Figure 6 C, D).

Statistical analysis was performed by comparing the number of dead fish and surviving fish on the final day of the experiment (day 10) between each of the three experimental groups and the control using the Fisher's Exact Probability Test[8]. Because multiple sample data were not available and each experimental group was individually compared to the control, the alpha level was adjusted using Bonferroni's Method[8]. This adjustment is a conservative measurement to limit the risk of a Type I error. The Bonferroni's Method application used an adjusted alpha level of 0.05/3 = 0.017 for comparison between each of the three experimental groups and the control. The P value for the control versus 0.15 M LiCl was 0.533681 and the result was not significant at an adjusted alpha level of 0.017. The P value for the control versus 0.30 M LiCl was 4.646×10^{-6} and was significant at an adjusted alpha level of 0.017. The p value for control versus 0.45 M LiCl was 9.886×10^{-17} and was significant at an adjusted alpha level of 0.017. A graph of zebrafish mortality (Figure 7) shows the number of deaths in each concentration group over the 10-day time course (Table 1).

Discussion

Control fish developed normally and were used as a standard for comparison to analyze lithium chloride effects. All fish exposed to 0.45 M LiCl died within 24 h and were not further analyzed. All fish exposed to 0.30 M LiCl failed to develop eyes. Other authors have reported cases of failed eye development but they did not observe such a severe effect of LiCl[3]. To resolve this discrepancy between our findings and the published data, the 0.30 M exposure group was replicated two additional times. Each of these subsequent trials (total of 58 fish in the three experiments) gave the same result of 100 percent failed eye development. This dramatic effect was coupled with defects in anterior-posterior development. Although fish survived for the 10-day period, limited

swimming and feeding behaviors were observed. The survival of the fish indicated that the fry must have been able to eat without the use of their eyes. Embryos exposed to 0.15 M LiCl showed some abnormal eye shape, and certain specimens developed only one eye. It is interesting to note that in light of the minor but apparent eye defects caused by LiCl, the fry did not reveal any behavioral abnormalities such as lack of feeding and swimming impairment. The embryos in the low dose acute exposure (0.15 M LiCl) were often more energetic and tended to avoid the pipette at a higher rate than control fish. This could be viewed as evidence for hormesis, but no analytical calculations were recorded to test that hypothesis. Hormesis occurs when exposure to a teratogen or historically harmful substance (e.g. ethanol) in very low doses actually has a beneficial effect on an organism[9]. Future studies should perform a range of low-dose exposures (e.g., 0.05 M, 0.08 M, 0.1 M, 0.12 M, and 0.15 M LiCl) and perform an analytical study of behavior compared to a control population to test for the possibility of hormesis.

Semithin sections of the control specimens revealed normal cellular organization of the eye as described by others[10] depicting all the distinct layers with the centrally located round lens. These layers are the ganglion cell layer followed by the bipolar neurons, the developing rods and cones, and finally the pigmented epithelium. When viewing specimens from the 0.15 M LiCl exposure group, the cell layers showed not only intact patterning, but also some spongiform degeneration in the external and internal plexiform layers. Even though normal cell patterning was found in the developing eye, there were cases when only one eye developed. In these cases usually only a small segment of the lens tissue was present where the eye should have been. It seems likely that after the initial few steps of eye development a subsequent failure of optic cup formation occurred. Similar defects were noticed in developmental studies with ethanol in zebrafish when optic tectum impairment was detected in embryos that developed only one eye[11]. These results suggest the possibility that exposure to lithium may also impair the formation the optic tectum. Future studies should be performed to see if impairment of the optic tectum happens in embryos exposed to LiCl. Specimens exposed to 0.30 M LiCl failed to develop eyes, if any; only rudimentary eye tissue could be detected. Scanning electron microscopy showed the complete absence of the eye.

Only slight differences in external eye morphology were found between control fish and fish exposed to 0.15 M LiCl under the scanning electron microscope. The eyes did not possess the perfect roundness as in the control eyes and appeared slightly more sunken. However, similar indentations were occasionally seen in control fish, so one should be cautious when attributing the change to a teratogenic effect of LiCl. Scanning electron images of the 0.30 M LiCl exposure group revealed a complete lack of eye tissue. While the skull and the eye socket developed, no optic cup was formed under these conditions. These results explain the apparent lack of eye tissue in histological sections of the 0.30 M LiCl group. Klein and Melton attribute the teratogenic effects of lithium chloride to the inhibition of the cell fate determinator, GSK-3β. Their data showed that GSK-3β is a kinase that may play a role in neurological signal transduction, and they believe treatment with lithium chloride inhibits the expression pathway[12]. It is possible that lithium chloride might have been involved in the disruption of cell fate determination during embryogenesis. Continued research should be conducted to monitor changes in protein expression and gene expression of developmental genes that are involved in zebrafish eye development.

Zebrafish mortality was analyzed for each of the three experimental groups and the control. The graph shows the trends of zebrafish mortality over the 10-day time course. All embryos died within one day when exposed to 0.45 M LiCl. The graph revealed that among all of the concentration groups,

the majority of fish deaths occurred before the second and third days. This is due to the fact that the embryos are the most sensitive to lethal developmental defects in the earlier stages of development. The Fisher Exact Probability Test with Bonferroni's Method adjustment[8] revealed a significant difference between the number of deaths in the 0.45 M LiCl experimental group versus the control and in the 0.30 M LiCl experimental group versus the control. Because the only variable between the groups was the concentration of lithium chloride, the deaths are attributed to the chemical effect. The 0.15 M LiCl deaths did not significantly differ from the control (P = 0.533681). Despite defects in eye shape, size, and development, the dose did not cause a significant change in mortality.

Acknowledgments

This research was supported by a grant from an anonymous donor to whom the authors are greatly appreciative. The authors would also like to thank Ms. Lauren Maltese for her technical assistance and Dr. Sundaram Moorthy for his critical edits to the manuscript.

References

[1]El-Mallakh, R.S. and A. Karipot, 2006. Chronic Depression in Bipolar Disorder. Am J Psychiatry **163**: 1337-1341.

[2]Viguera, A.C., R. Nonacs, L.S. Cohen, L. Tondo, A. Murray and R.J. Balsessarii, 2000. Risk of recurrence of bipolar disorder in pregnant and nonpregnant women after discontinuing lithium maintenance. America Psych. Assoc. **157**: 179-184.

[3]White, J.N., 2004. The effects of different concentrations of lithium chloride on the development of *Brachydanio rerio* embryos. Experiments in Developmental Biology at Swarthmore College. 1-8.

[4]Stachel, S.E., D.J. Grunwald and P.Z. Myers, 1993. Lithium perturbation and *goosecoid* expression identify a dorsal specification pathway in the pregastrula zebrafish. Development **117:** 1261-1274.

[5]Westerfield, M., 2000. *The zebrafish Book: A guide for the laboratory use of zebrafish* (*Danio rerio*). University of Oregon Press, Eugene.

[6]Karnovsky, M.J. 1965. A formaldehyde glutaraldehyde fixative of high osmolarity for use in electron microscopy. J Cell Biol. **27**: 137A.

[7]Spurr, A.R, 1969. A low viscosity epoxy resin and embedding medium for electron microscopy. J. Ultrastruct. Res. **26**: 31-43.

[8]Samuels, M.L. and J.A. Witmer, 1999. *Statistics for the Life Sciences*. 2nd Ed. Prentice Hall, Upper Saddle River, NJ.

[9]Calabrese E.J. 2002. Hormesis: changing view of dose response, a personal account of the history and current status. Mutation Research/ Reviews in Mutation Research. **511**: 181-189.

[10]Raymond, P.A., L.K. Barthel, R.L. Bernardos, and J.J. Perkowski, 2006. Molecular characterization of retinal stem cells and their niches in adult zebrafish. BMC Developmental Biology **6**: 36.

[11]Arenzana, F.J., M.J. Carvan III, J. Aijon, R. Sanchez-Gonzalez, R. Arevalo and A. Porteros, 2006. Teratogenic effects of ethanol exposure on zebrafish visual system development. Neurotoxicology and Teratology **28**: 342-348.

[12]Klein, P. S. and D.A. Melton, 1996. A molecular mechanism for the effect of lithium on development. Nat. Aca. of Sci. **93**: 8455-8459.

Student Membership

We encourage your students to become Associate Members in MACUB. Many of them will go on to graduate and professional schools. Their membership, participation and attendance at conferences such as these can enhance the experiences they include on their applications and discuss during interviews.

2009 MACUB Conference Registration Form
42nd Annual MACUB Conference at Kingsborough Community College
Saturday, October 24, 2009

❑Dr.
❑Prof.

❑Regular Member
❑Full-Time Faculty
❑Mr.
❑Ms.
❑_____

❑Student Member[1]
❑Member's Spouse/Guest
❑Adjunct Faculty[1]

* Name: _____ * School Phone: _____
* Department: _____ * Fax: _____
* School: _____ * E-Mail: _____
* Address: _____
_____

*The above information may appear in a Directory of Members unless you indicate otherwise.

Home Address: _____
_____
_____

Home Phone: _____

I prefer MACUB mailings to be sent to my:

❑School ❑ Home[1]

[1]Student and adjunct mailings will normally be sent to your home address.

	Early Bird by 9/21	In Advance by 10/14	On-Site 10/24	
❑Regular Member	$45	$50	$55	Includes 2010 Membership dues, conference registration, continental breakfast and luncheon.
❑Student Associate Membership	$35	$35	$40	Includes 2010 Associate Membership dues, conference registration, continental breakfast and luncheon.
❑Member's Spouse/Guest	$35	$35	$40	Includes conference registration, continental breakfast and luncheon.

❑I will not be attending the Conference but enclosed is my 2010 membership dues.
❑Regular Member $20 ❑Student Member $10

Return this registration form by October 14, 2009
Please make checks payable to: MACUB
Send registration form and check to:
Dr. Paul Russo
Division of Natural Sciences & Mathematics
Bloomfield College
467 Franklin Street
Bloomfield, NJ. 07003

Registration fees are refundable upon written notification by **October 14, 2009.** The membership fee ($20 for regular members and $10 for student members) will be deducted. *No refunds will be given postmarked after October 14, 2009.*

Call for Manuscripts

Publish your manuscripts in *In Vivo*
Follow the Instructions for Authors on the inside cove and submit your manuscripts electronically to the Editorial Board at invivo@mec.cuny.edu

Visit the M.A.C.U.B. web site at
www.macub.org

The MACUB web site is now up and running. We now call for members to use the web site for registration information. Register for the 42nd Annual Fall Conference on-line. Submit your poster presentation abstract on-line. Submit your member paper presentation on-line. If you are a MACUB member in good standing and have a web site that you would like linked to our web site, submit the URL address to: gsarinsky@kbcc.cuny.edu

The Metropolitan Association of College and University Biologists thanks the following Affiliate Members for their support:

Addison-Wesley/Benjamin Cummings
BioRad Laboratories
Brooks/Cole, Thomson Learning
EDVOTEK
John Wiley & Sons
Kendall/Hunt Publishing Company
McGraw Hill Publishers
Medgar Evers College
Micro-Optics Precision Instruments
Pasco Scientific
Prentice Hall Publishing
Shimadzu Scientific
Thomson Learning, Brooks/Cole

M A C U B

Dr. Edward J. Catapane
Department of Biology
Medgar Evers College
1150 Carroll Street
Brooklyn, New York 11225